ANTICANCER RESEARCH *45*: 1305-1328 (2025)
doi: 10.21873/anticanres.17518

Review

Biomarkers Predicting Progression and Prognosis of Ductal Carcinoma *In Situ* (DCIS)

RHEA BHALA[1#], LESLIE FAYE CANDO[1,2#], PRISHA VERMA[1], TAIWO ADESOYE[1] and ANJANA BHARDWAJ[1]

[1]Breast Surgical Oncology, The University of Texas MD Anderson Cancer Center, Houston, TX, U.S.A.;
[2]College of Medicine, University of the Philippines Manila, Manila, Philippines

Abstract

This review describes the histopathological and molecular features distinguishing high-risk ductal carcinoma *in situ* (DCIS) from low-risk DCIS and their progression to invasive breast cancer (IBC). We summarize key alterations that occur in various compartments of the breast tissue such as myoepithelial cells, luminal epithelial cells, and the immune environment. Evidence suggests that DCIS and IBC share a largely similar genome, with comparable transcriptomes across various grades of DCIS and IBC. However, some studies report transcriptional up-regulation of multiple genes in luminal epithelial cells of high-risk DCIS. High-risk DCIS is also characterized by loss of genes that are crucial for maintaining the integrity of the myoepithelium, a physical barrier that keeps the cancer cells from invading surrounding tissue. High-grade DCIS is also characterized by global hypomethylation, but hypermethylation of select gene promoters also occurs. Immune environment changes that correlate with high-risk DCIS include overall increased T cell, B cell, and macrophage infiltration. Despite the active immune environment, these immune cells are in suppressed state and are characterized by increased presence of immunosuppressive Tregs, immunosuppressive M2, tumor-associated macrophages (TAMs), an immunophenotypic switch of fibroblasts into cancer-associated fibroblasts (CAFs) and lesser amounts of protective cytotoxic T cells. Several long noncoding RNAs also play a role in driving the premalignant phenotypic changes in normal breast epithelial and DCIS cells. Further validating the ability of these prognostic biomarkers for predicting DCIS progression will help reduce overtreatment while effectively managing the patients with DCIS that are at high risk of progression to IBC.

Keywords: DCIS, breast cancer, invasive breast cancer, molecular markers, prediction, genetic, epigenetic, DNA methylation, cancer progression, LncRNA, immune, review.

[#]These Authors contributed equally to this work.

Anjana Bhardwaj, Ph.D., Department of Breast Surgical Oncology, The University of Texas MD Anderson Cancer Center, Houston, TX 77030, U.S.A. E-mail: abhardwaj@mdanderson.org

Received February 5, 2025 | Revised February 27, 2025 | Accepted March 4, 2025

This is an open access article under the terms of the Creative Commons Attribution License, which permits use, distribution and reproduction in any medium, provided the original work is properly cited.
©2025 The Author(s). Anticancer Research is published by the International Institute of Anticancer Research.

Introduction

Ductal carcinoma *in situ* (DCIS) is a non-invasive, non-obligate precursor lesion to invasive breast cancer (IBC) made up of malignant epithelial cells in the basement membrane of the terminal duct lobular units of the breast (1). DCIS develops after benign hyperproliferative state (atypical hyperplasia or atypia) and precedes to the onset of IBC during breast cancer progression. DCIS consists of a wide range of lesions that differ based on their morphology, grade, genomic profile, and clinical presentation (1). With the increase in screening mammography utilization since 1980, the diagnosis of DCIS has substantially increased from 5% to ranging from 15.0% to 28.2% (2-5). In 2023, over 55,720 women were diagnosed with DCIS in the United States (6, 7). Molecular alterations similar to IBC have been observed in DCIS, such as copy number variations (CNV), gene mutations, and gene expression changes (8-10).

The primary goal of treating DCIS is to prevent progression to IBC, through treatment modalities such as surgery, radiotherapy, and hormonal therapy. However, the main challenge is identifying which DCIS lesions will progress, and which will not. Currently, clinicians use various factors, such as the size and grade of DCIS lesions in addition to molecular markers, to estimate the risk of progression. Nonetheless, the predictive accuracy of these factors remains imperfect, and many patients with low risk of progression to IBC overtreated (11). Furthermore, the diagnosis and treatment of DCIS take a psychosocial toll on patients and their families. On the other hand, a significant number of DCIS lesions progress to IBC (1, 12) and would benefit from treatment, creating a clinical dilemma.

Molecular characterization of DCIS can potentially bring forward biomarkers for early detection of DCIS, improve prediction of DCIS progression, and help manage patients effectively to reduce unnecessary treatment. Thus, the purpose of this review is to summarize the current knowledge of prognostic biomarkers in DCIS, a topic of great interest and clinical importance. This review focuses on the interplay of genetic and epigenetic alterations in cancer cells along with aberrations in the immune microenvironment that contribute to the progression of DCIS to invasive breast cancer. This review aims to support clinicians and patients alike in shared decision-making in the management of DCIS using available prognostic markers.

Histopathological Features and Heterogeneity of DCIS

One of the primary histopathological characteristics of DCIS is the proliferation of neoplastic epithelial cells confined within the mammary ducts (12). As a non-obligate precursor for IBC, the major diagnostic criteria that differentiates it from IBC is the presence of intact basement membrane and myoepithelial cell layer in DCIS (13). DCIS displays heterogenous growth patterns including cribriform (irregular, glandular spaces formed by tumor cells), micropapillary (small finger-like projections of tumor cells within the ducts), solid/comedo (tightly packed tumor cells without differentiating glandular spaces with characteristic central duct space necrosis), and papillary (finger-like projections covered by tumor cells with a fibrovascular core) (13, 14). These patterns are used to facilitate diagnosis and determine the extent of DCIS. However, since there can be more than one pattern observed in a lesion, the more clinically significant system to classify DCIS is based on nuclear grade. Low-grade DCIS present as evenly spaced uniform cells with small regular nuclei, with infrequent mitosis and necrosis. Intermediate-grade DCIS exhibit some abnormal growth characteristics, with moderate cell size and shape variations. However, high-grade DCIS is composed of large, irregularly spaced pleomorphic cells with an irregular nuclear contour and high nuclear-to-cytoplasmic ratio (15). High-grade DCIS is more likely to recur or progress to IBC and in relation to the architecture, the presence of comedo pattern is associated with high-grade DCIS and therefore an increased risk of progression to IBC (16-18).

Overall, histopathological assessment is crucial for identifying and characterizing DCIS and it provides helpful prognostic and diagnostic information. Since these histopathologic characteristics are the basis of DCIS

grading, which is one of the essential features used for predicting the possibility of disease progression, it guides the development of optimal treatment plans. However, these methods have limitations in predicting DCIS progression and are subject to differences in technical acuity of pathologists in analyzing samples. This challenge, along with the biological heterogeneity of DCIS grades, supports the need for better risk prediction markers and tailored treatment approaches.

DCIS Diagnosis and Upstaging Rates

The diagnosis of DCIS has dramatically increased due to the increased utilization of screening mammography (2, 3, 5, 19). One in every 1,300 mammography screenings leads to a diagnosis of DCIS (3). Multiple studies have estimated that progression rates of DCIS to IBC range from 14% to 53% over at least a 10-year period (1, 20). However, these rates are not uniform as progression is influenced by multiple factors, such as the grade, molecular characteristics, and size of the DCIS lesions, as well as individual patient factors (21). There is also considerable variation in the rate of progression of DCIS to invasive disease depending on the sensitivity of the diagnostic test and the type of the risk prediction model used. This can vary from 20% to 91% (21, 22). However, DCIS can also remain indolent and never progress to IBC despite being left untreated (15). The natural history of low-grade DCIS may extend more than four decades (23). Estimates of overdiagnosis range from 34% to 72% for patients aged 50-74 years who underwent screening every other year (21). To add complexity to the challenges in DCIS management, it is also important to consider that a significant number of DCIS lesions, ranging from 6-33%, are upstaged to invasive carcinoma upon excision (24-28). This corresponds to under-staging in approximately one in four DCIS diagnoses highlighting a potential risk of conservative management, with no surgery or radiation therapy. Herein lies the challenge in the management of DCIS. We must consider a significant number of DCIS cases that should be upstaged to IBC but also pay attention to concerns about overdiagnosis which can lead to unnecessarily aggressive treatment.

DCIS Treatment Options

The primary goal of DCIS treatment is to prevent progression to IBC. Currently, the management options for DCIS include breast-conserving surgery (BCS) or mastectomy, which can be followed by adjuvant radiation therapy (RT) and hormonal therapy in eligible patients. However, National Comprehensive Cancer Network (NCCN) cautions that while RT significantly decreased the risk of recurrence in patients with DCIS, the overall risk of recurrence is low. Furthermore, the choice of local treatment does not impact overall disease-related survival and therefore the individual's preferences for risk reduction must be considered (29-31). In attempts to de-escalate treatment to avoid higher treatment costs and adverse effects, several trials have examined if BCS can be done alone without RT (32-34). This is especially for low-risk patients, wherein the benefits of RT do not outweigh the harms associated with radiation toxicity (*e.g.*, myelo-suppression, pneumonitis, fatigue, secondary cancer) and the risk of recurrence is unlikely to be significantly reduced by RT (35). Additionally, several trials such as the LORIS Trial [Surgery versus Active Monitoring for LOw RISk Ductal Carcinoma in Situ (DCIS); ISRCTN27544579] in the UK and COMET Trial (Comparing an Operation to Monitoring, With or Without Endocrine Therapy For Low Risk DCIS; NCT02926911) in the United States, and the LORD trial in the Netherlands (NCT02492607) are comparing the risks and benefits of standard surgery and active monitoring for low-risk DCIS with variable definition. Active monitoring of patients with low-risk DCIS includes mammograms every 6 to 12 months for at least 5 years and performing a magnetic resonance imaging (MRI) to determine if surgical intervention is necessary. The COMET trial is a randomized pragmatic non-inferiority clinical trial that enrolled 995 patients with low-risk DCIS defined as grade 1-2, hormone receptor (HR)-positive, human epidermal growth factor receptor 2 (HER2) negative DCIS randomized to surgery or active monitoring (36). After median follow up of 36.9 months, the authors reported noninferiority of both treatment modalities in the intention

to treat and per protocol analysis. The primary endpoint of 2-year ipsilateral invasive cancer rate was 5.9% in the guideline-concordant arm compared to 4.2% in the active monitoring arm. Of note, nonacceptance of primary treatment in 29% favoring the active monitoring arm was observed highlighting significant patient interest in active monitoring (36). Patient reported outcomes in both groups showed similarities in quality of life regardless of treatment strategy (36). Taken together, results of the COMET trial demonstrate that in the short-term, active monitoring of low-risk DCIS is a reasonable approach. The LORIS trial has completed recruitment while the LORD trial is still ongoing.

DCIS Progression and Predictive Biomarkers

NCCN recommends the following work up for DCIS: history and physical examination, bilateral diagnostic mammography, pathology review, determination of tumor estrogen receptor (ER) status, and breast MRI when indicated. Among these, ER status may influence decision for disease management, as it is used to determine the benefit of adjuvant endocrine therapy for risk reduction (37). Evidence suggest that ER negativity does not significantly correlate with an incidence of a future ipsilateral breast event among patients (38). This highlights the scarcity of biomarkers that can predict DCIS progression in patients that can heavily impact the choice of management.

We will discuss what is currently known about genomic and transcriptomic changes, immune-related markers, and epigenetic factors that are associated with DCIS progression. We selected these biomarkers as they have been studied in the context of DCIS recurring or progressing to IBC especially in patient samples. While several biomarkers require further investigation and clinical validation, these studies will enrich our repertoire of potential biomarkers for DCIS progression and hopefully aid in making better clinical decisions when treating patients with DCIS.

Genomic changes in DCIS progression. Somatic genetic alterations include point mutations, copy number alterations (CNA), loss of heterozygosity (LOH), and chromosomal alterations. Genomic instability provides growth advantage to cells and is a fundamental characteristic of cancer's heterogeneous nature. Understanding the stage-specific genomic differences may help find patterns that can predict DCIS progression.

Using comparative genomic hybridization (CGH), Buerger *et al*. (1999) found that well-differentiated and intermediately-differentiated DCIS (low-risk) had losses of 16q whereas poorly-differentiated DCIS (high-risk) had a higher frequency of amplifications in 17q12 and 11q13 and a higher average rate of genetic imbalances. Importantly, they first noted that adjacent IBC had a genetic pattern almost identical to DCIS and hence suggested that DCIS are genetically advanced, direct precursors of IBC (39). In support of these findings, a study by Vincent-Salomon *et al*. (2008) showed significant CNA overlap between DCIS and invasive ductal carcinoma (IDC), and these genomic changes correlated with modifications of the gene expression profiles in DCIS and IBC (40). Similarly, Johnson *et al*. (2012) performed genomic analysis of synchronous DCIS and IDC and noted that DCIS is an advanced, genomically unstable tumor that in many cases has already acquired most determinants of invasiveness. Matched IDC and DCIS samples had highly similar copy number profiles (41). However, they noted four chromosomal regions of loss (3q, 6q, 8p, and 11q) and four regions of gain in IDC (5q, 16p, 19q and 20) that were recurrently affected in IDC and not in DCIS. Gorringe *et al*. (2015) studied the genome-wide copy number and loss of heterozygosity in a cohort of patients with pure DCIS treated with wide local excision alone (42). Interestingly, their results showed that DCIS cases with recurrence had a higher fraction of the genome altered compared to non-recurrent cases (p=0.026), more copy number changes especially gain of 20p12 and 20q11 in DCIS recurrence as IBC (p<0.01), and chromosome 10 allelic imbalance (42). While there may be some conflicting results on the genomic profile alterations of DCIS as it progresses to IBC, it must be noted that these differences may be due to the limitations of available samples as well as the variations in the sequencing/

profiling platforms used. A meta-analysis of 26 studies by Rane *et al*. (2015) characterized the somatic CNA in DCIS cases with and without IBC. They identified 339/851 cytobands that showed significant differences in the gain and loss frequencies ($p \leq 0.05$) with overrepresentation of genes in pathways known to be affected in breast carcinogenesis (41%) such as transmembrane signaling receptor activity, G-protein-coupled receptor activity, cadherin protein class, wingless-type MMTV integration site family (Wnt) pathway, and inflammation (43). From these analyses, they concluded that DCIS and IDC harbor similar numbers of genetic aberrations in more than 76% of the genome – suggesting that a significant part of the decision of whether disease will progress into IDC probably occurs early at the stage of DCIS (43). Similarly, Doebar *et al.* (2019) noted a high genomic concordance between synchronous DCIS and IBC (44). Supporting this, a recent genomic study on primary DCIS and their matched recurrences observed that most mutations and CNAs were already established in the primary DCIS, and they found no clear genomic markers for invasive progression. Frequency of CNA across DCIS and invasive recurrences also showed highly similar chromosomal gains and losses (10). Similar results were found by Kaplan *et al.* (2024) noting that most small variants and CNVs were shared between co-occurring DCIS and IBC lesions, unsurprisingly with IBC having a higher degree of additional mutations. In terms of chromosomal instability, pure DCIS also showed almost the same degree as invasive cancers but noted that low-grade DCIS had a higher 16q loss (p=0.002) and high-grade DCIS had higher 8p loss (p=0.005) (9).

With these studies, it appears that these stage-specific genomic differences between DCIS and IBC are limited (10, 40, 43, 45). While there are key alterations noted such as GATA-binding protein 3 (*GATA3)* mutation positivity [odds ratio (OR) for relapse=5.5; 95% confidence interval (CI)=0.63-76.7], phosphatidylinositol 3-kinase catalytic subunit alpha (*PIK3CA),* tumor protein p53 gene (*TP53),* and mitogen-activated protein kinase kinase kinase 1 (*MAP3K1)* mutations, amplification of cyclin D (*CCND)1* and oncogene *MYC*, CNVs in myeloid cell leukemia-1 (*MCL1*), Cyclin-dependent kinases regulatory subunit 1 (*CKSB1*), and epidermal growth factor receptor-2 (*ERRB2*), and some patterns of loss and gain of chromosomal copy alterations among others, the genomic landscape between these two stages remains significantly similar (9, 41, 46, 47).

Gene Expression Markers

Molecular subtyping of DCIS. In attempts to transition from histopathological nuclear grading which demonstrated a significant amount of heterogeneity for DCIS, some studies focused on molecular subtyping of DCIS lesions similar to approach for IBC (48, 49). In breast cancer, these subtypes reflect the expression of the nuclear hormone receptors ER and progesterone receptor (PR), and epidermal growth factor receptor-2 (ERBB2/HER2) as the major regulators of cancer cell growth and survival. Zhou *et al.* (2010) investigated the prognosis of DCIS in relation to the molecular subtypes defined by immunohistochemistry (IHC). They studied a cohort of 458 women with a primary DCIS diagnosis, performed microarray gene-profiling, and determined who developed local DCIS vs. invasive recurrence. Their results showed that while DCIS with basal-like features had a higher risk of local recurrence [hazard ratio (HR)=1.8, 95%CI=0.9-4.2] and a higher risk of developing invasive cancer (HR=1.9; 95%CI=0.7-5.1) compared to other subtypes, the difference was not statistically significant (50). Furthermore, when they focused on a subgroup of women who only had BCS, the risk for progression of basal-like DCIS was doubled (HR=1.9; 95%CI=0.7-5.1) but still not significantly higher. Interestingly, they also analyzed histopathologic factors such as nuclear grade, size, necrosis and margins and found that the grade did not relate to prognosis (HR=1.0, 95%CI=0.3-3.9) and suggested that molecular subtyping by IHC might indeed be more useful (50).

To investigate the use of HER2 for molecular subtyping of DCIS, Roses *et al.* (2009) studied 106 patients diagnosed with DCIS by either core needle or excisional biopsies and

performed IHC staining for ER, PR, and HER2 (51). Their results showed that HER2 was the only significant predictor for the presence of invasive disease after multivariate adjustment (OR=6.4; p=0.01) (51). Nagasawa *et al.* (2021) also proposed that HER2 amplification is critical marker (46). Yang *et al.* (2022) showed that HER2 over-expression had a 15.15% 5-year overall secondary breast events (SBEs) and is the only independent prognostic factor among the subtypes (p=0.012) (52). Another study showed that there are more high-risk cases and higher risk of IBE recurrence in HR-HER2+ subtype than in HR+HER2- subtype (53). However, these are not consistent with other studies hence the importance of HER2 status as a prognostic indicator of DCIS has been unclear (50, 54, 55). Furthermore, there was no statistically significant benefit to using trastuzumab with RT in HER2 amplified DCIS (56). Since the results do not affect management, NCCN guidelines do not recommend HER2 testing for DCIS (57).

These findings provide insufficient evidence and clinical significance to support the use of molecular subtyping as a marker of DCIS progression. However, they can be used as candidates for biomarker studies, and a guiding tool to subcategorize heterogenous DCIS.

Cancer associated genes in DCIS progression. Cancer is a remarkably complex disease that results from cells acquiring capabilities that allow them to proliferate uncontrollably and invade surrounding tissues. These characteristics were described by Hanahan and Weinberg (2000) as the hallmarks of cancer (58). Here, we discuss several gene expression changes that have been shown to have an association with DCIS progression and are key mediators of cancer hallmarks, such as cell proliferation and survival, DNA repair, and invasion (58).

Tumor suppressor gene p16/ cyclin-dependent kinase inhibitor 2A (CDKN2A) which regulates cell cycle through inhibition of cyclin-dependent kinases, is co-expressed with cell proliferation marker Ki67 and cyclooxygenase-2 (COX-2), and associates with basal-like behavior in DCIS cases (59). In agreement, Kerlikowske *et al.,* (2010) also found that the eight-year risk of DCIS progressing to a subsequent IBC was higher (p=0.018) for women with initial DCIS lesions that were detected by palpation (HR=2.7; 95%CI=1.4-5.5), or were p16, COX-2, and Ki-67 triple positive (HR=1.9; 95%CI=0.8-4.3) than for women with lesions detected by mammography and were p16, COX-2, and Ki-67 negative (54). These observations were made in a nested case-control study in a population-based cohort of 1162 women who were diagnosed with DCIS and treated with lumpectomy alone (54) and ER, PR, Ki-67, p53, p16, HER2, and COX-2 were assayed by IHC staining of paraffin-embedded DCIS tissues to identify factors or combinations associated with progression to IBC.

In support of these findings, COX-2 has been associated with tumor survival, invasion, and metastasis in cancer and has been noted to correlate with nuclear grade in pure DCIS, albeit with limited samples (60, 61). Similarly, Boland *et al*. (2004) showed that the median COX-2 expression in DCIS and invasive cancer are significantly greater than in normal breast ducts (p<0.0001), although there was no difference between DCIS and invasive cancer in median expression (p=0.59) (62). However, Ki-67, a proliferation marker already established as a marker of aggression in IBC, did not show any association in DCIS associated with IBC compared to pure DCIS (63). While these markers show limited power individually, combining these factors may have a better prognostic power for predicting DCIS progression (54).

The most fundamental hallmark of cancer cells is their ability to sustain cell proliferation and survival. Several genes and pathways may influence DCIS progression by affecting cell proliferation in high-risk cases, including Aurora Kinase A (AURKA/STK15). This serine-threonine kinase plays a crucial role in centrosome duplication and mitotic regulation. In a 2022 study, Miligy *et al*. investigated the levels of Aurora Kinase A in a cohort consisting of pure DCIS (n=776) and DCIS associated with invasive breast cancer (n=239) (64). For patients with pure DCIS treated with breast conserving surgery only, high AURKA expression was associated with both local and invasive recurrence (HR=6.9, 95%CI=2.7-7.0, p<0.0001) and even

when restricting to invasive recurrence only (HR=3.9, 95%CI=1.7-7.1, p=0.001) (64).

Dettogni *et al*. (2020) found that genes related to the cell cycle, Hedgehog signaling, and Wnt pathways were associated with the aggressiveness of DCIS through gene expression profiling of normal breast tissue, pure DCIS, and DCIS occurring alongside invasive breast cancer (65). Supporting the notion of early gene expression changes, pure DCIS showed the most altered gene expression profile compared to normal breast tissue. Additionally, three differentially expressed genes, fibroblast growth factor 2 (*FGF-2*; fold change 1.5, p=0.004), growth arrest-specific 1 (*GAS1*; fold change 2.67, p=0.007), and secreted frizzled related protein 1 (*SFRP1*; fold change 2.61, p=0.001), were identified by comparing pure DCIS with DCIS co-occurring with IBC, suggesting their possible role in the acquisition of invasiveness in DCIS (65). In another study, Eslarraj *et al.* (2020) found that the RNA and protein levels of B cell lymphoma 9 (*BCL9*), which plays a role in the canonical Wnt signaling, was significantly elevated during the time of DCIS progression to invasive disease (66). Furthermore, they showed that BCL9 interacts with Signal transducer and activator of transcription 3 (*STAT3*), affecting the expression of STAT3-regulated gene targets such as integrin β3 (*ITGB3*) and matrix metallopeptidase 16 (*MMP16*). To demonstrate the role of BCL9 in DCIS progression, they showed that rosemary extract, which attenuates BCL9/β-catenin dependent transcription, resulted in loss of *BCL9* expression and subsequent down-regulation of targets *integrin β3* and *MMP16*, causing a dose-dependent reduction in the number of invasive lesions (p=0.00924) (66).

Guo *et al*. (2019) described the MAPK-interacting serine/threonine-protein kinase 1 (MNK1)/nodal growth differentiation factor (NODAL) signaling axis as a promoter of DCIS progression through the promotion of cell proliferation, induction of cancer stem cell properties, and invasion (67). They found that MNK1 activity is elevated in high-grade DCIS and IDC compared with low-grade DCIS patient samples. Knockout of MNK1 using CRISPR/Cas9 suppresses NODAL expression, which in turn prevents IDC conversion and reduces tumor relapse and metastasis (67). Additional evidence for the role of the MNK/NODAL signaling pathway in DCIS progression was provided by the finding that the MNK1/2 inhibitor SEL201 effectively blocked DCIS progression *in vivo* (67). NRAS, an upstream regulator of MAPK signaling that promotes cell proliferation and survival, is also associated with low ER and high Ki-67 levels, markers indicative of a higher risk of DCIS progression (68). Over-expression of oncogene NRAS induces a basal-like gene signature in DCIS cells and may drive the emergence of basal IBC, highlighting its potential as a therapeutic target to prevent DCIS progression (68). One of the ways RAS signaling pathway has been a critical player in the growth-promoting pathways of breast tumorigenesis is through its role in the HER2/Neu/ epidermal growth factor receptor (EGFR)/RAS signaling. Behling *et al*. (2013) showed that expression of Siah E3 ubiquitin ligase 1 (SIAH1), a "gatekeeper" for the HER2/EGFR/RAS signal transduction, is significantly higher in DCIS cases associated with recurrence compared to those without recurrence (p<0.0001) and also higher in primary DCIS with invasive recurrence (p=0.036) (69). In addition, SIAH1 expression in DCIS (OR=1.31, 95%CI=1.06-1.62, p=0.013) and adjacent normal breast tissue (OR=1.1, 95%CI=1.03-1.16, p=0.003) were both significant predictors of disease recurrence with a sensitivity of 76% and specificity of 79% (69).

Impaired DNA repair results in genomic instability, which is another of the hallmarks of cancer. Al-Kawaz *et al.* (2021) found high expression of DNA repair protein flap structure-specific endonuclease 1 (FEN1) to correlate with cancer progression (70, 71). Normal breast tissues express low levels of FEN1, pure DCIS shows relatively higher expression, and DCIS co-occurring IBC exhibit high levels of FEN1. Moreover, high expression of FEN1 associates with aggressive and high-risk features such as higher nuclear grade, proliferation index, HR negativity, and triple-negative phenotype. Conversely, DNA polymerase β (POLβ), another key player in DNA repair, shows a gradual reduction in expression from normal breast tissue to DCIS and lowest expression in IBC. Low POLβ associate with aggressive DCIS features and serves as an independent

predictor of recurrence (HR=0.490, 95%CI=0.256-0.936, *p*=0.031) (70, 71).

Finally, epithelial-to-mesenchymal transition (EMT) is one of the major events in cancer tumorigenesis that allows invasion and metastasis, a hallmark of cancer. A study by Treekitkarnmongkol *et al.* showed that epigenetic activation of SRY-box transcription factor 11 (*SOX11*) is associated with recurrence and progression of DCIS to IBC (72). *SOX11* was noted to promote an epithelial/mesenchymal tropism, and it is associated with increased distant metastasis in IBC (73). First, they showed that SOX11 was detected only in DCIS lesions compared to matched normal breast tissue, and this was correlated with high DCIS grade and recurrence score. Further, they showed that activation of a serine/threonine kinase AKT, an upstream regulator of SOX11, correlated with chromatin accessibility and enrichment of histone modifying enzyme enhancer of zeste homolog 2 (EZH2) on *SOX11* promoter thereby up-regulating *SOX11* expression. They used human cell lines and mouse models of DCIS disease progression and validated it in DCIS cohorts, which showed a statistically significant difference in overall relapse-free survival (RFS) between SOX11+ and SOX11− DCIS (HR=1.9, 95%CI=1.2-2.9; *p*=0.003) (72).

Gene expression changes associated with myoepithelial layer and stromal alterations. The myoepithelial layer serves not only as a contracting unit for milk secretion but as a structural barrier between mammary epithelial cells and the surrounding stroma. There is no surprise that in DCIS, a confined neoplastic lesion, the integrity of myoepithelial layer prevents it from being a full-blown invasive lesion. There have been several studies that provide evidence for the role of the myoepithelial layer in preventing *in situ* tumors from invasion. Myoepithelial cells lose differentiation markers such as tumor protein 63 (p63), calponin-1, and α-smooth muscle actin (α-SMA) prior to losing their structural integrity. Understanding the molecular signatures of normal myoepithelial cell differentiation can provide useful information about predicting high risk DCIS.

An early histopathologic study by Man *et al*. (2003) noted that 42.7% of DCIS cases contained disrupted myoepithelial cell layer and these were associated with higher proliferation rates and loss of ER expression on adjacent cells in the ducts (74). They also noted different patterns of loss of heterozygosity and microsatellite instability in the ER-negative compared to ER-positive epithelial cells in the same ducts overlying the disrupted myoepithelial cells. These suggest interaction changes causing degradation of the myoepithelial layer and clonal expansion and invasion of cells in these disrupted foci (74). Hu *et al.* (2008) also studied the role of myoepithelial cells and surrounding fibroblasts in the progression of *in situ* lesions using human DCIS and primary breast tumors and their results further support the role of myoepithelial layer in DCIS progression (75). Based on their immunohistochemical analysis and gene expression profiling, they identified extensive crosstalk among tumor growth factor-β (TGF-β), hedgehog (Hh), cell adhesion, and p63 signaling pathways in DCIS cells and demonstrated critical role of TGF-β and Hh pathways in DCIS progression since a decrease in these pathways resulted in loss of myoepithelial cells and accelerated progression to invasion (75).

Loss of smooth muscle actin (SMA)-related protein calponin has also been reported to be associated with DCIS progression in mouse models (76). In line with these findings, p63+TCF7+ myoepithelial cells are also decreased in the normal breasts of breast cancer gene (BRCA)1 and BRCA2 germline mutation carriers compared to non-carriers suggesting these molecular alterations are indicative of higher risk of breast cancer (77). In agreement with the role of p63 and transcription factor (TCF)7 in higher breast cancer risk in general, high-risk DCIS also exhibit lower numbers of p63+TCF7+ myoepithelial cells (77). These findings support the role of p63 and TCF7 in normal differentiated myoepithelial cell phenotype and their loss may contribute to the increased breast cancer risk of BRCA mutation carriers. This can also potentially lead to the loss of differentiated myoepithelial cells in DCIS promoting progression to

invasion. As DCIS progresses to an invasive phenotype, breast myoepithelial layer stretches and leads to increase in duct size. This mechanical expansion of myoepithelium is characterized by myoepithelial expression of cell integrin β6 and periductal expression of extracellular matrix protein fibronectin (78, 79). These integrin β6 positive aberrant myoepithelial cells have been shown to promote the invasive progression of DCIS into IDC via TGF-β and matrix metalloproteinase 9 (MMP9) signaling activation (80). Approximately 96% of DCIS cases that had concurrent IBC have been found to express αvβ6-integrin, whereas 52% of the non-high grade DCIS and 69% of high grade DCIS express αvβ6-integrin (81).

Loss of caveolin 1 (Cav-1) in the fibroblasts, a key component of the surrounding stromal microenvironment of myoepithelial layer, predicts early DCIS progression to invasive breast cancer (82). When down-regulated, Cav-1 is associated with DCIS recurrence and progression to IBC (HR=3.569, p=0.000013) (82). Martinez-Outschoorn *et al*. (2010) demonstrated that breast cancer cells induced Cav-1 down-regulation in adjacent stromal fibroblasts via a paracrine mechanism by causing autophagic/lysosomal degradation (83). Furthermore, co-culture also caused normal fibroblasts to acquire a cancer-associated fibroblast phenotype characterized by Cav-1 down-regulation, increased expression of myofibroblast markers and extracellular matrix proteins, and constitutive activation of TGF-β/Smad2 signaling. Interestingly, chloroquine was found to inhibit the degradation of Cav-1 and thus seems like a promising drug for the prevention and treatment of DCIS. Clinical studies that are testing the efficacy of chloroquine such as the Preventing Invasive Breast Neoplasia with Chloroquine (PINC) Trial (ClinicalTrials.gov ID NCT01023477) showed measurable reduction in proliferation of DCIS lesions and enhanced immune cell migration into the duct. Loss of stromal Cav-1 is often accompanied by the gain of stromal monocarboxylate transporter 4 (MCT4) when matched *in situ* and invasive breast cancer samples are compared (75%, p<0.0001) (84). Progression of DCIS to invasive state is characterized by loss of Cav-1, which causes metabolic reprogramming of stromal cells to enhance the expression of MCT4 that plays a role in aerobic glycolysis and energy metabolism. This is needed to support the increased cell proliferation and growth of surrounding epithelial cells and in turn increased need for energy (84).

A large-scale transcriptomic study by Rebbeck *et al.* (85) modelled a continuous trajectory of the gene expression patterns of DCIS lesions and noted a progressive loss in basal layer integrity heading towards IDC supporting the study of Man *et al.* (74). This was coupled with expression of genes associated with EMT not only at the transition to invasive disease but even much earlier in the process, and finally, followed by an increase in cell proliferation. They identified calcium/calmodulin dependent protein kinase II inhibitor 1 (*CAMK2N1*), motor neuron and pancreas homeobox 1 (*MNX1*), adenylyl cyclase 5 (*ADCY5*), homeobox C11 (*HOXC11*) and ankyrin repeat domain 22 (*ANKRD22*) as potential biomarkers, whose reduced expression is associated with the progression of DCIS to invasive breast cancer (85).

Gene expression panels and prognostic scoring systems in predicting DCIS progression. In the recent years, there have been several studies that investigated panels of genetic markers for DCIS progression, in part due to the advent of improved technologies for multi-omic studies. With this, the focus has shifted to finding the panels of genetic or gene signatures to stratify DCIS recurrence and progression as compared to individual biomarkers as these panels may better account for the heterogeneity of breast cancer pathogenesis. Currently, there are DCIS scoring systems that have been clinically validated in patients with DCIS: Oncotype DX DCIS score, DCISion RT Decision score, and Oncotype 21-gene recurrence score. Oncotype DX uses a panel of 12 genes including seven cancer related genes corresponding to a cell proliferation group and progesterone receptor (*PR)*, with five reference genes. In the ECOG E5194 study group population, the DCIS Score was significantly associated with developing an ipsilateral breast event (IBE) (HR=2.31, 95%CI=1.15-4.49; p=0.02) and an even higher HR for invasive breast disease (HR=3.68,

95%CI=1.34-9.62; *p*=0.01) (86, 87). This was also validated in an Ontario population-based DCIS cohort where an HR of 1.78 (95%CI=1.31-4.41, *p*=0.04) (88) was noted. DCISionRT (PreludeDx) uses markers including COX-2, FOXA1, HER2, Ki-67, PR, and SIAH2 with four clinicopathologic features (age, size, margin status, palpability). This was validated in a study population of 526 and showed that a biological signature driven decision score was correlated with 10-year IBC (HR=3.1, 95%CI=1.5-6.5; *p*=0.003) and IBE risks (HR=1.9, 95%CI=1.1-3.1, *p*=0.016) (89). Finally, the Oncotype 21-gene recurrence score (RS), which is a panel of 21 different genes related to proliferation, invasion, HER2, and estrogen with 5 reference genes that have been validated in invasive breast cancer, was also tested in DCIS (90). Their results showed that women with high recurrence score treated by breast conserving surgery alone had a 1.8-fold increase in risk of invasive breast recurrence and a 21.7% cumulative 20-year risk of invasive recurrence compared with a low RS; hence helping identify which individuals RT can be given to reduce risk of death from IBC (88). These genomic scoring tools represent a significant advancement in the personalization of treatment decision-making for patients with DCIS.

Immune System in DCIS Progression

The interplay between cancer cells and immune cells plays a pivotal role in cancer development and progression. According to the cancer immunoediting theory that describes the role of immune system in cancer development, the initial elimination phase of immunosurveillance involves pro-inflammatory immune cells eliminating aberrant preneoplastic cells to prevent cancer development. During the equilibrium phase, characterized by impaired immuno-surveillance, new genetic variants of cancer cells evolve, allowing these cells to survive. This impaired immune environment fails to completely eradicate the tumor cells but keeps tumor growth in check. Finally, in the escape phase, tumor cells form a palpable mass, create an immunosuppressive environment, and completely evade immunosurveillance (91).

A key feature of DCIS progression is the loss of the surrounding ductal epithelium, which limits the exposure of ductal cancer cells to surrounding immune cells. Understanding these critical immune alterations that occur during the progression of preinvasive DCIS to invasive breast cancer will help differentiate high-risk DCIS from those with a low risk of progression. DCIS and IBC are characterized by distinct immune cell compositions and their functional states. Numerous studies have shown that the immune environment is largely suppressed in invasive breast cancer. However, studies focused on characterizing the immune environment in DCIS are rather limited. Invasive breast cancer is enriched in T helper cells, regulatory T cells, macrophages, B cells, and PD-L1+ T cells compared to DCIS (92, 93). This suppressive immune environment in invasive breast cancer is associated with more aggressive subtypes like TNBC and is a predictor of poor prognosis. Conversely, anti-tumor CD8+ cytotoxic T cells, Type 1 helper T cells (Th1), M1 macrophages, and natural killer (NK) cells are associated with better breast cancer prognosis. Research efforts aimed at determining whether the immune environment of DCIS is associated with disease progression have yielded conflicting results, as outlined below.

Tumor-infiltrating lymphocytes (TILs) in DCIS progression. Multiple studies have measured the levels of tumor-infiltrating lymphocytes (TILs) in H&E-stained archived tissue sections of DCIS to assess their power in predicting the high risk of DCIS progression. Despite their favorable prognosis in IBC, the significance of TILs in DCIS progression is less clear, with studies displaying contradictory results.

A number of studies reported that high levels of TILs in DCIS are largely associated with a higher chance of recurrence and progression to IBC (94-100). Recently, Li *et al.* analyzed a large dataset with 718 patients and found that higher TIL density is associated with several adverse prognostic indicators in DCIS, such as larger lesion size, higher cytonuclear grade, the presence of necrosis, ER

negativity, and HER2 over-expression (100). DCIS with high TIL numbers were also found to have a three-fold higher risk of developing ipsilateral IBC than DCIS with low TIL levels (100). Thompson *et al.* also discovered that more aggressive ER-negative DCIS exhibited higher numbers of all TIL subsets compared to ER-positive DCIS (101). In ER-positive DCIS, the immune environment was more tumor-protective, as indicated by a higher ratio of CD8/FoxP3 than in ER-negative DCIS. Although TILs are more prevalent in the more aggressive ER- and HER2+ DCIS, this increase in TILs has failed to significantly associate with DCIS recurrence in several studies (102, 103). Some of these conflicting results could be due to the simplistic nature of TIL scoring on H&E slides without consideration of the TIL type and functional state.

Recent studies have used techniques like multiplexed immunofluorescence and a combination of global profiling with single-cell methods to distinguish various cell types within tissue-infiltrating lymphocytes. In one such study performed by Alcazar *et al*., aimed at delineating the co-evolution of cancer cells and the immune microenvironment during tumor progression using matched DCIS and recurrent IBC samples, it was shown that there was a decrease in activated GZMB+CD8+ T cells in HER2+ and triple-negative invasive breast cancer compared to DCIS (104). This was particularly evident in DCIS cases that recurred locally as IBC, implying that decreased immune activity, particularly of activated T cells, may be necessary for invasive progression (104). Furthermore, T-cell receptor clonotype diversity was significantly higher in DCIS than in invasive breast cancer, indicating a more robust immune system in DCIS relative to IBC (104). In addition to the lower levels of protective cytotoxic T cells in recurrent IBC, there was an increase in co-inhibitory immune checkpoint receptor programmed death-ligand 1(PD-L1) and cytotoxic T-lymphocyte associated protein 4 (CTLA4)-expressing T cells in triple-negative subtype IBCs (104). Although DCIS tumor epithelial cells express low levels of PD-L1, high proportions of PD-L1+ TILs have been observed in high-grade DCIS (101). Levels of immunosuppressive T cells, such as Tregs, vary between DCIS and IBC (92). Regulatory T cells (Tregs), characterized by the presence of forkhead box P3 (FOXP3), are suppressive immune cells that increase during breast tumor progression, suggesting that this could be used to predict the risk of invasive progression. However, FOXP3+ T cells have not been consistently detected in DCIS. However, T cell immunoreceptor with Ig and ITIM domains (TIGIT)-expressing T cells are more frequent in triple-negative DCIS (104).

Macrophages. Chronic inflammation plays a pivotal role in cancer development and often associates with a higher risk of breast cancer progression. A wide variety of secretory molecules and immune cell types including macrophages form this inflammatory tumor microenvironment. Tumor-associated macrophages (TAMs) make up the majority of tumor cell contents and correlate with poor cancer prognosis and low efficacy of checkpoint inhibitor therapy in cancer patients (50, 105-108). TAMs are immuno-suppressive and functionally similar to M2 macrophages. M1 macrophages, however, are pro-inflammatory and tumor inhibitory. Current understanding in the field points towards a theory that an immunosuppressive environment in the tumor leads to the generation of tumor-associated macrophages (TAMs), which in turn secrete factors that further promote cancer progression (109).

An increase in both pro- and anti-tumor macrophages has been reported in a p53-null mouse model of early breast cancer progression (110). Macrophages were found to be recruited to high-risk ductal hyperplasias, where they are differentiated and polarized toward a tumor-promoting phenotype (110). Similarly in human DCIS, macrophages are more abundant in high-grade and cribriform DCIS than in low/intermediate-grade DCIS (111). The prognostic relevance of macrophages in DCIS is also highlighted by studies that report higher macrophage density in DCIS to be associated with poorer prognostic parameters (112). Importantly, higher stromal cluster of differentiation (CD) 163 + macrophage density, indicative of M2 phenotype, predicted both recurrence and ipsilateral invasive recurrence (112). In contrast, Hoskoppal *et al.* did not find any correlation between

intratumoral CD163 content, as measured by IHC staining, and DCIS grade (113). In this study, although a trend for higher stromal CD163 expression was observed with higher-grade DCIS, it was not statistically significant. The authors point towards the lack of uniform criteria for the interpretation of high vs. low CD163 staining and low interobserver correlation as a possible limitation of data analysis (113).

A multi-omics study that inferred immune cell composition from RNA sequencing of young-onset DCIS samples and paired normal breast tissue/blood samples by applying deconvolution analyses revealed that the majority of these high-risk DCIS were "immune hot" (114). These immune-hot DCIS were characterized by features such as an increase of M1 macrophages, CD4+ memory resting T cells, CD8+ T cells, memory B cells, CD4+ memory activated T cells, naïve B cells, and M2 macrophages compared to the "cold" group. In addition, there was higher expression of Programmed cell death protein 1 (PDCD1) and cytotoxic T-lymphocyte antigen 4 (CTLA4), which suggests that immune escape mechanisms may contribute to the malignant characteristics of "immune hot" DCIS. Overall, "immune hot" DCIS that were HER2 or basal-like subtypes exhibited a combination of activated but immunosuppressive gene signatures indicating an active yet evasive immune response (114).

Understanding the molecular mechanisms that cause macrophage homing and their polarization to a protumor phenotype will help differentiate high-risk DCIS and potentially prevent DCIS progression. Chemokines are secretory molecules that play a role in the recruitment of immune cells during inflammation and cancer. The interplay of chemokine C-C motif chemokine ligand 2 (CCL2) and its receptor, C-C motif chemokine receptor 2 (CCR2) signaling in breast cancer cells has been found to regulate macrophage recruitment and promote breast cancer progression. CCL2 mediates the progression of DCIS through the phosphorylation of MET proto-oncogene, receptor tyrosine kinase (MET), enhancing cancer cell proliferation, survival, migration, and glycolysis (115).

Fibroblasts. Since cancer is considered a wound that does not heal, similar to a wound, tumor cells release and express several factors that promote clotting. This procoagulant environment, created by fibroblast-dependent mechanisms, further supports cancer progression. Normal fibroblasts, which are crucial for maintaining the structural and functional integrity of normal breast tissue, are replaced by cancer-associated fibroblasts during cancer progression. This phenotypic switch occurs at the preinvasive stage, as evidenced by increased fibroblast expression of tumor-promoting clotting activation markers such as tissue factor (TF), thrombin, and protease-activated receptor (PAR)1 and PAR2 (116), in DCIS and IBC compared to normal breast tissue. The fibroblast procoagulant phenotype also correlates with aggressive breast cancer subtypes and reduced survival (116). Over-expression of fibroblast activation protein-alpha (FAP-α) (alone or in combination with Golgi phosphoprotein 3 in carcinoma cells) in stromal fibroblasts is highly predictive of DCIS recurrence and progression into invasive breast cancer (117). The immunophenotype conversion of stromal fibroblasts from CD34(+) α-SMA(–) FAP-α(–) in DCIS to CD34(–) α-SMA(+) FAP-α(+) in IBC may also serve as an important determinant of DCIS with microinvasion (118).

Cancer-associated fibroblasts constitute an important component of the tumor immune microenvironment in solid tumors, modulating the transition from DCIS to IDC through their secretion of factors that modify the surrounding stromal matrix (119, 120). An interplay between cancer cells and cancer- associated fibroblasts (CAFs) seems to be involved in breast cancer progression. Croizer *et al*. reported that cancer cells drive the transition of immuno-protective CAFs towards immunosuppressive extracellular matrix (ECM)-producing CAFs via a dipeptidyl peptidase 4 (DPP4)- and a transcriptional coactivator Yes-associated protein (YAP)-dependent mechanism (121). In turn, these immunosuppressive ECM-CAFs polarize triggering receptor expressed on myeloid cells 2 (TREM2)+ macrophages and regulatory NK and T cells to induce an immunosuppressive cell state.

Similarly, immuno-protective CAFs are associated with folate receptor beta (FOLR2)+ macrophages. In nutshell, inflammatory and myofibroblastic CAF clusters are differentially localized within breast tumors and may potentially predict invasive recurrence of DCIS (121).

CCL2/CCR2 signaling between fibroblasts and breast epithelial cells has emerged as another mechanism of DCIS progression. Brummer *et al*. found that fibroblasts derived from DCIS patient samples accelerate progression from DCIS to IDC through CCR2-dependent mechanisms, mediated by up-regulation of aldehyde dehydrogenase 1 family member A1 (*ALDH1A1*) and down-regulation of high-temperature requirement protein A2 (*HTRA2*) in DCIS cells (122). There is also evidence of interleukin-6 (IL-6)-mediated paracrine crosstalk between preinvasive human DCIS cells and human breast CAFs in the progression to invasive breast carcinoma in 3D cultures (123).

To test whether the overall state of tumor microenvironment can predict DCIS cases that are likely to metastasize, formalin-fixed, paraffin-embedded (FFPE) sections of 117 high-grade DCIS cases with a history of recurrence and non-high-grade DCIS cases were analyzed (124). The study revealed that high-risk DCIS features were associated with high levels of FoxP3+ T cells, CD68+ and CD68+ proliferating cell nuclear antigen (PCNA+) macrophages, human leukocyte antigen – DR isotype (HLA-DR)+ cells, CD4+ T cells, CD20+ B cells, and total TILs compared to non-high-grade DCIS. Additionally, CD8+HLADR+ T cells, CD8+HLADR- T cells, and CD115+ immune cell populations were associated with the risk of DCIS recurrence (124).

A comprehensive study by Almekinders *et al*. screened more than 10,000 patients and investigated the prognostic value of immune cell characteristics for predicting the risk of ipsilateral IBC (iIBC) in 141 patients with pure DCIS and matched iIBC, followed up over a median of 12 years (125). Of these, 77 women went on to develop iIBC. The study reported that high stromal immune cell density (T cells, activated T cells, Tregs, B cells, and macrophages) correlates with factors (ER negativity, HER2 positivity, Ki-67, grade, and periductal fibrosis) known to be associated with invasive recurrences. However, none of these immune factors were found to be independent predictors of the risk of subsequent iIBC after the diagnosis of primary, pure DCIS (125).

Interplay Between Myoepithelium and Immune Environment

Myoepithelium is a gate keeper that restricts the tumor cell escape in DCIS and their exposure to surrounding immune cells. Disruption of the myoepithelial layer, that forms a physical barrier, is a hallmark of progression of DCIS to invasive breast carcinoma.

Risom *et al*. constructed a 2D spatial atlas of breast cancer progression to identify features in primary DCIS associated with the risk of invasive relapse using human breast tissues that captured the full spectrum of breast cancer progression, from normal tissue to DCIS and matched ipsilateral IBC recurrences (126). The authors found that coordinated transformation of ductal myoepithelium and surrounding stroma plays a central role in cancer progression by establishing a tumor-permissive niche that favors local invasion. Surprisingly, contrary to the widely accepted role of myoepithelium in breast cancer, Risom *et al*. found DCIS samples with more intact myoepithelium and high E-cadherin expression to be of higher risk of ipsilateral invasive recurrence following primary DCIS resection (126). Conversely, thin, broken, low-E-cadherin expressing myoepithelium present in non-progressor tumors was correlated with a more reactive desmoplastic stroma with more immune cells, CAFs, and collagen remodeling. The authors acknowledge that the 2D nature of the analyses and the small dataset of matched DCIS/IBC samples are key limitations of the study, pending further direct cause-effect causal studies on myoepithelial integrity and changes in the immune microenvironment (126).

Nonetheless, a compromise in myoepithelial barrier function appears to be enough to expose tumor cells to immune surveillance, eventually leading to immune cell exhaustion. Supporting this concept, Mitchell *et al*. found

that a subset of clinically and pathologically defined low-risk DCIS lesions had lost calponin-1 (a marker of differentiated myoepithelium) and had exhausted CD8+ T cells, similar to the majority of high-risk DCIS lesions (127). These observations suggest that this subset of DCIS lesions has a high risk of progression (127).

Epigenetic Factors

Environmental factors and lifestyle increase the risk of breast cancer, as suggested by 5-fold higher incidence rate of breast cancer in women in Western countries relative to Asian women. The impact of these epigenetic factors becomes clearer with a subsequent increase in breast cancer rate of Asian women living in Western countries (128). Environment can shape gene expression and health outcomes through heritable epigenetic mechanisms such as DNA methylation. DNA methylation along with polycomb repressor complex and histone modifications determine the overall state of chromatin (repressive or activated) and ultimately determine the state of cell plasticity in normal cellular development and cancer. Global hypomethylation is a general feature of cancers including breast cancer (129), however, hypermethylation of multiple gene promoters has been reported. These defects in DNA methylation lead to silencing of tumor suppressors and other genes involved in DNA damage repair, cell survival, and cell proliferation through hypermethylation of their promoters (130).

Numerous studies provide evidence that DNA methylation of gene promoters is an early event, and a majority of DNA methylation changes have already occurred prior to invasive breast carcinoma (131-134). In support of this model, Fleischer *et al*. found DNA methylation profiles of DCIS to be radically different compared with normal breast tissue (more than 5,000 genes) while the changes between DCIS and IBC were comparably modest (about 1,000 genes) (135). Interestingly, the affected pathways suggested that many of the changes may not occur in the tumor, but in infiltrating cells suggesting epigenetic reprogramming of immune cells. Moelans *et al.* also found DCIS to be epigenetically as advanced as IDC as no additional changes in promoter methylation between DCIS and IDC were found in a set of 25 analyzed genes (136). Although these findings point towards DCIS to be as advanced as IBC in term of epigenetic changes, higher grade DCIS was not found to have significantly higher methylation levels of glutathione s-transferase pi 1 (*GSTP1*) and *CDKN2A* (p16) compared to low grade DCIS (136). In support of the role of DNA methylation in high DCIS grade and in predicting of its malignant potential, Hoesel *et al*. also found hypermethylation of *MINT31* to be associated with unfavorable lesion characteristics such as ER negativity in DCIS (134). In addition, hypermethylation of adenomatous polyposis coli (*APC*), *CCND2*, cadherin 1(*CDH1*), retinoic acid receptor beta (*RARB*) have been associated with higher nuclear grade of DCIS. Additionally, hypermethylation of ATP binding cassette subfamily B member 1 (*ABCB1*), forkhead box C1 (*FOXC1*), Ras association domain family member 1 A (*RASSF1A*), cilia and flagella associated protein (*DLEC1*), protein phosphatase 2 regulatory subunit B beta (*PPP2R2B*), and phosphatase and tensin homolog (*PTEN*) have been linked with the unfavorable characteristics of DCIS such as HER2 amplification, Ki67 index, and TP53 mutation (137-140). Fleischer *et al*. also found a prognostic signature based on methylation level of 18 cytosine-phosphate-guanine (*CpGs*) to be associated with DCIS patient prognosis (135). To determine which DCIS is likely to progress, it is also imperative to consider its molecular subtype and take a subtype specific approach to obtain prognostic information. Bergholtz *et al.* studied gene expression, DNA methylation, and copy number analysis in 57 pure DCIS and 313 IBC cases and found basal-like DCIS tumors to be highly similar to IBC of Luminal A subtype, in terms of higher degree of differentiation, lower proliferation and lower genomic instability than basal-like IBC (141).

Although these studies suggest correlation between methylated genes and DCIS aggressiveness, studies that assessed the prognostic power of methylation to predict clinical outcome are limited. In one such longitudinal study Johnson *et al*. profiled 40 ER positive patient with

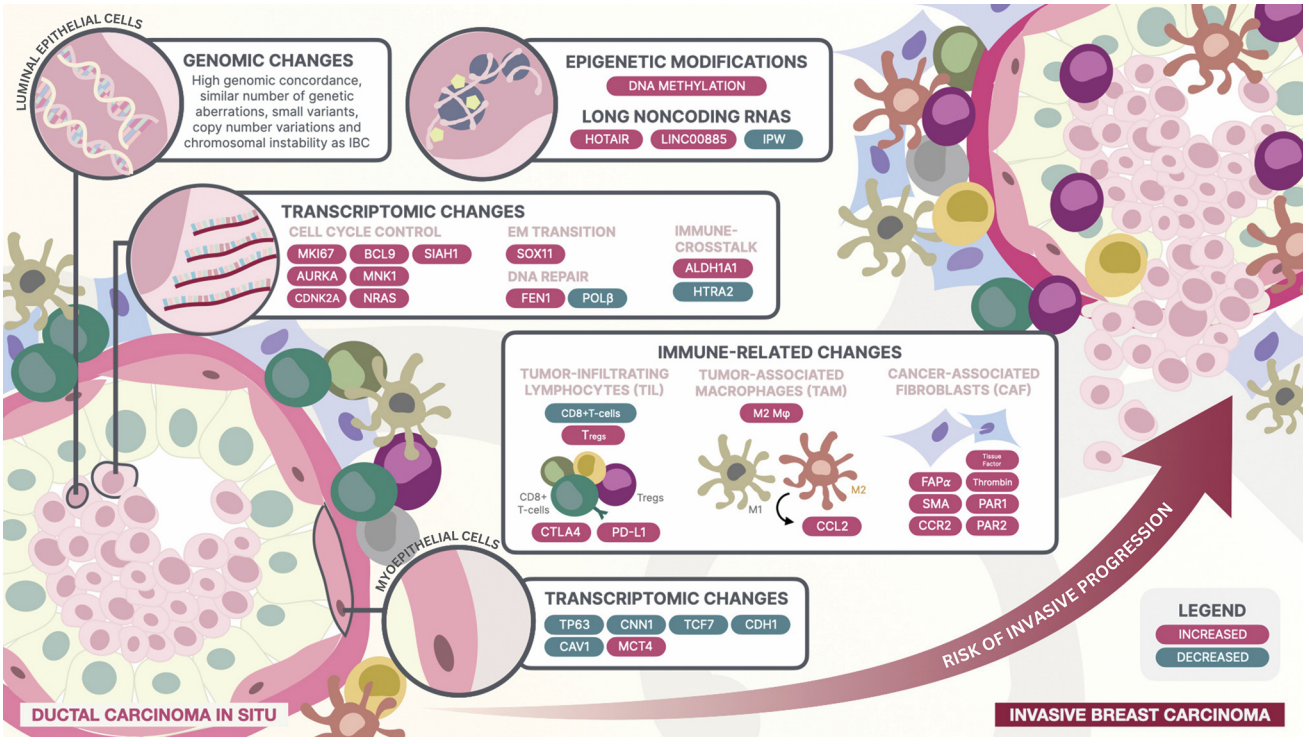

Figure 1. *Summary of molecular markers of DCIS progression. Here we summarize the potential key biomarkers that can predict invasive progression of ductal carcinoma in situ (DCIS) lesions. At the genomic level, there are limited stage-specific differences that help predict DCIS progression. However, several transcriptomic changes in the luminal epithelium may play a role in cancer hallmarks. These include genes involved in cell cycle control [MKI67 (Ki-67), CDNK2A (p16), AURKA (Aurora kinase A), BCL9 (B-cell CLL/lymphoma 9 protein), MNK1 (MAPK-interacting serine/threonine-protein kinase 1), NRAS (N-Ras), SIAH1 (E3 ubiquitin-protein ligase SIAH1)], DNA repair [flap structure-specific endonuclease 1 (FEN1), polymerase β (POLβ)], and epithelial-to-mesenchymal (EM) transition [SRY-box transcription factor 11 (SOX11)]. In myoepithelial cells, loss of several genes that help maintain the integrity of the myoepithelial layer [TP63 (p63), CNN1 (calponin-1), TCF7 (transcription factor 7), CDH1 (cadherin-1), and CAV1 (caveolin-1)] help drive DCIS progression. Immune-related changes include a higher level of immunosuppressive Tregs, lower level of protective cytotoxic T cells, higher level of immunosuppressive M2 tumor-associated macrophages (TAMs), and an immunophenotypic switch of fibroblasts into cancer-associated fibroblasts (CAFs) to induce an immunosuppressive state. Finally, early epigenetic reprogramming by hypermethylation of several gene promoters in DCIS and long noncoding RNAs have been associated with DCIS progression.*

DCIS of which 13 patients progressed to IBC in order to identify methylation alterations that contribute to progression of DCIS (142). Homeobox-containing genes such as polycomb group gene targets and genes involved with limb morphogenesis were found to be altered (142). Interestingly, these methylation alterations correlated strongly with their gene expression in an independent set of early stage ER positive breast cancers suggesting that differential methylation of these sites may directly contribute to an increased risk of invasion through aberrations in gene expression (142).

LNCRNAs

LncRNAs have been widely reported to play an instrumental role in gene regulation and cancer progression. Multiple lncRNAs have been reported to be associated with breast cancer and correlate with aggressiveness of DCIS such as HOX transcript antisense RNA (*HOTAIR*), *HOTAIRM1*, *long intergenic non-protein coding RNA (LINC)00885*, *LINC01011* and *LINC01024*. Laboratory evidence suggests that *LINC00885* and *HOTAIR* over-expression induces premalignant phenotypic

changes in normal breast epithelial and DCIS cells by increasing cell proliferation, motility, and migration, and altering 3D growth (143, 144). Imprinted gene in the Prader-Willi syndrome region (*IPW)* is another lncRNA that is down-regulated in DCIS and its ectopic expression inhibits DCIS growth (145). However, it remains to be tested whether the levels of these lncRNA can predict the prognosis of patients with DCIS.

Conclusion and Unanswered Questions

Figure 1 highlights potential biomarkers and phenomena that correlate/predict DCIS progression to IBC (Figure 1). The studies discussed in here bring forward potential novel biomarkers and prevention strategies for DCIS that are at high risk of progression to IBC; however, we must keep in mind that these were conducted mostly comparing either DCIS lesions with matched IBC cases or from DCIS lesions co-occurring with IBC and may fail to capture true DCIS progression. Future studies are needed, where these biomarkers are tested for their positive predictability in serial samples collected from longitudinal follow-up studies of patients with DCIS that are tracked for progression to invasive breast cancer. Understanding these mechanisms and utilizing the underlying biomarkers that can correctly predict DCIS progression will add more to our arsenal in identifying patients with poor prognoses or those who would benefit from our available treatment modalities. Identifying molecular mechanisms and biomarkers that play a causal role in the progression of DCIS will guide novel drug development for prevention of DCIS progression. Novel therapies along with improved risk stratification models will also ensure that individuals with DCIS receive the most appropriate and personalized treatment.

Conflicts of Interest

The Authors have no conflicts of interest to declare in relation to this study.

Authors' Contributions

RB contributed to literature search and writing; LFC contributed to literature search, writing and preparing figures; PV contributed to literature search and summarizing results; TA contributed to writing of the review; AB contributed to conception of the review, literature search, and writing.

Acknowledgements

The Authors would like to thank Ashli R Villarreal and Amy L Ninetto from Department of scientific publications at MD Anderson Cancer Center for thorough editorial review to improve the clarity and flow of the manuscript.

Funding

Not applicable.

References

1 Martínez-Pérez C, Turnbull AK, Ekatah GE, Arthur LM, Sims AH, Thomas JS, Dixon JM: Current treatment trends and the need for better predictive tools in the management of ductal carcinoma *in situ* of the breast. Cancer Treat Rev 55: 163-172, 2017. DOI: 10.1016/j.ctrv.2017.03.009

2 DeSantis CE, Ma J, Goding Sauer A, Newman LA, Jemal A: Breast cancer statistics, 2017, racial disparity in mortality by state. CA Cancer J Clin 67(6): 439-448, 2017. DOI: 10.3322/caac.21412

3 Ernster VL, Ballard-Barbash R, Barlow WE, Zheng Y, Weaver DL, Cutter G, Yankaskas BC, Rosenberg R, Carney PA, Kerlikowske K, Taplin SH, Urban N, Geller BM: Detection of ductal carcinoma *in situ* in women undergoing screening mammography. J Natl Cancer Inst 94(20): 1546-1554, 2002. DOI: 10.1093/jnci/94.20.1546

4 Nicosia L, Bozzini AC, Penco S, Trentin C, Pizzamiglio M, Lazzeroni M, Lissidini G, Veronesi P, Farante G, Frassoni S, Bagnardi V, Fodor C, Fusco N, Sajjadi E, Cassano E, Pesapane F: A model to predict upstaging to invasive carcinoma in patients preoperatively diagnosed with low-grade ductal carcinoma *in situ* of the breast. Cancers (Basel) 14(2): 370, 2022. DOI: 10.3390/cancers14020370

5 Virnig BA, Tuttle TM, Shamliyan T, Kane RL: Ductal carcinoma *in situ* of the breast: a systematic review of incidence, treatment, and outcomes. J Natl Cancer Inst 102(3): 170-178, 2010. DOI: 10.1093/jnci/djp482

6 Siegel RL, Miller KD, Wagle NS, Jemal A: Cancer statistics, 2023. CA Cancer J Clin 73(1): 17-48, 2023. DOI: 10.3322/caac.21763

7 American Cancer Society: Key statistics for breast cancer. Available at: https://www.cancer.org/cancer/types/breast-cancer/about/how-common-is-breast-cancer.html

8 Hwang ES, DeVries S, Chew KL, Moore DH 2nd, Kerlikowske K, Thor A, Ljung BM, Waldman FM: Patterns of chromosomal alterations in breast ductal carcinoma *in situ*. Clin Cancer Res 10(15): 5160-5167, 2004. DOI: 10.1158/1078-0432.CCR-04-0165

9 Kaplan HG, Dowdell AK, Berry AB, Shimol RB, Robinson FL, Carney CA, Piening BD: Multi-omic profiling of simultaneous ductal carcinoma *in situ* and invasive breast cancer. Breast Cancer Res Treat 205(3): 451-464, 2024. DOI: 10.1007/s10549-024-07270-5

10 Lips EH, Kumar T, Megalios A, Visser LL, Sheinman M, Fortunato A, Shah V, Hoogstraat M, Sei E, Mallo D, Roman-Escorza M, Ahmed AA, Xu M, van den Belt-Dusebout AW, Brugman W, Casasent AK, Clements K, Davies HR, Fu L, Grigoriadis A, Hardman TM, King LM, Krete M, Kristel P, de Maaker M, Maley CC, Marks JR, Menegaz BA, Mulder L, Nieboer F, Nowinski S, Pinder S, Quist J, Salinas-Souza C, Schaapveld M, Schmidt MK, Shaaban AM, Shami R, Sridharan M, Zhang J, Stobart H, Collyar D, Nik-Zainal S, Wessels LFA, Hwang ES, Navin NE, Futreal PA, Grand Challenge PRECISION consortium, Thompson AM, Wesseling J, Sawyer EJ: Genomic analysis defines clonal relationships of ductal carcinoma *in situ* and recurrent invasive breast cancer. Nat Genet 54(6): 850-860, 2022. DOI: 10.1038/s41588-022-01082-3

11 Hahn E, Rodin D, Sutradhar R, Nofech-Mozes S, Trebinjac S, Paszat LF, Rakovitch E: Can molecular biomarkers help reduce the overtreatment of DCIS? Curr Oncol 30(6): 5795-5806, 2023. DOI: 10.3390/curroncol30060433

12 Pinder SE: Ductal carcinoma *in situ* (DCIS): pathological features, differential diagnosis, prognostic factors and specimen evaluation. Mod Pathol 23 Suppl 23: S8-S13, 2010. DOI: 10.1038/modpathol.2010.40

13 Dabbs DJ: Breast pathology. Elsevier Health Sciences, 2023.

14 Pal SK, Lau SK, Kruper L, Nwoye U, Garberoglio C, Gupta RK, Paz B, Vora L, Guzman E, Artinyan A, Somlo G: Papillary carcinoma of the breast: an overview. Breast Cancer Res Treat 122(3): 637-645, 2010. DOI: 10.1007/s10549-010-0961-5

15 Wang J, Li B, Luo M, Huang J, Zhang K, Zheng S, Zhang S, Zhou J: Progression from ductal carcinoma *in situ* to invasive breast cancer: molecular features and clinical significance. Signal Transduct Target Ther 9(1): 83, 2024. DOI: 10.1038/s41392-024-01779-3

16 Fisher ER, Land SR, Saad RS, Fisher B, Wickerham DL, Wang M, Costantino JP, Wolmark N: Pathologic variables predictive of breast events in patients with ductal carcinoma *in situ*. Am J Clin Pathol 128(1): 86-91, 2007. DOI: 10.1309/WH9LA543NR76Y29J

17 Okumura Y, Nishimura R, Osako T, Arima N: Higher nuclear grade indicates an invasiveness of ductal carcinoma in breast cancer. J Clin Oncol 26(15_suppl): 22228-22228, 2008. DOI: 10.1200/jco.2008.26.15_suppl.22228

18 Shekhar MP, Tait L, Pauley RJ, Wu GS, Santner SJ, Nangia-Makker P, Shekhar V, Nassar H, Visscher DW, Heppner GH, Miller FR: Comedo-ductal carcinoma *in situ*: A paradoxical role for programmed cell death. Cancer Biol Ther 7(11): 1774-1782, 2008. DOI: 10.4161/cbt.7.11.6781

19 White E, Lee CY, Kristal AR: Evaluation of the increase in breast cancer incidence in relation to mammography use. J Natl Cancer Inst 82(19): 1546-1552, 1990. DOI: 10.1093/jnci/82.19.1546

20 Erbas B, Provenzano E, Armes J, Gertig D: The natural history of ductal carcinoma *in situ* of the breast: a review. Breast Cancer Res Treat 97(2): 135-144, 2006. DOI: 10.1007/s10549-005-9101-z

21 van Ravesteyn NT, van den Broek JJ, Li X, Weedon-Fekjær H, Schechter CB, Alagoz O, Huang X, Weaver DL, Burnside ES, Punglia RS, de Koning HJ, Lee SJ: Modeling ductal carcinoma *in situ* (DCIS): an overview of CISNET model approaches. Med Decis Making 38(1_suppl): 126S-139S, 2018. DOI: 10.1177/0272989X17729358

22 Grimm LJ, Rahbar H, Abdelmalak M, Hall AH, Ryser MD: Ductal carcinoma *in situ*: state-of-the-art review. Radiology 302(2): 246-255, 2022. DOI: 10.1148/radiol.211839

23 Sanders ME, Schuyler PA, Dupont WD, Page DL: The natural history of low-grade ductal carcinoma *in situ* of the breast in women treated by biopsy only revealed over 30 years of long-term follow-up. Cancer 103(12): 2481-2484, 2005. DOI: 10.1002/cncr.21069

24 Buonomo OC, Pellicciaro M, Materazzo M, Berardi S, Gigliotti PE, Caspi J, Meucci R, Perretta T, Portarena I, Dauri M, Pistolese CA, Vanni G: Surgical treatments for ductal carcinoma *in situ* (DCIS) in elderly patients. Anticancer Res 43(4): 1555-1562, 2023. DOI: 10.21873/anticanres.16305

25 Grimm LJ, Ryser MD, Partridge AH, Thompson AM, Thomas JS, Wesseling J, Hwang ES: Surgical upstaging rates for vacuum assisted biopsy proven DCIS: implications for active surveillance trials. Ann Surg Oncol 24(12): 3534-3540, 2017. DOI: 10.1245/s10434-017-6018-9

26 Park AY, Gweon HM, Son EJ, Yoo M, Kim JA, Youk JH: Ductal carcinoma *in situ* diagnosed at US-guided 14-gauge core-needle biopsy for breast mass: Preoperative predictors of invasive breast cancer. Eur J Radiol 83(4): 654-659, 2014. DOI: 10.1016/j.ejrad.2014.01.010

27 Brennan ME, Turner RM, Ciatto S, Marinovich ML, French JR, Macaskill P, Houssami N: Ductal carcinoma *in situ* at core-needle biopsy: meta-analysis of underestimation and predictors of invasive breast cancer. Radiology 260(1): 119-128, 2011. DOI: 10.1148/radiol.11102368

28 Dillon MF, McDermott EW, Quinn CM, O'Doherty A, O'Higgins N, Hill AD: Predictors of invasive disease in breast cancer

when core biopsy demonstrates DCIS only. J Surg Oncol 93(7): 559-563, 2006. DOI: 10.1002/jso.20445
29 Goodwin A, Parker S, Ghersi D, Wilcken N: Post-operative radiotherapy for ductal carcinoma *in situ* of the breast – A systematic review of the randomised trials. Breast 18(3): 143-149, 2009. DOI: 10.1016/j.breast.2009.04.003
30 Holmberg L, Garmo H, Granstrand B, Ringberg A, Arnesson LG, Sandelin K, Karlsson P, Anderson H, Emdin S: Absolute risk reductions for local recurrence after postoperative radiotherapy after sector resection for ductal carcinoma *in situ* of the breast. J Clin Oncol 26(8): 1247-1252, 2008. DOI: 10.1200/JCO.2007.12.7969
31 McCormick B, Winter K, Hudis C, Kuerer HM, Rakovitch E, Smith BL, Sneige N, Moughan J, Shah A, Germain I, Hartford AC, Rashtian A, Walker EM, Yuen A, Strom EA, Wilcox JL, Vallow LA, Small W Jr, Pu AT, Kerlin K, White J: RTOG 9804: a prospective randomized trial for good-risk ductal carcinoma *in situ* comparing radiotherapy with observation. J Clin Oncol 33(7): 709-715, 2015. DOI: 10.1200/JCO.2014.57.9029
32 Di Saverio S, Catena F, Santini D, Ansaloni L, Fogacci T, Mignani S, Leone A, Gazzotti F, Gagliardi S, De Cataldis A, Taffurelli M: 259 Patients with DCIS of the breast applying USC/Van Nuys prognostic index: a retrospective review with long term follow up. Breast Cancer Res Treat 109(3): 405-416, 2008. DOI: 10.1007/s10549-007-9668-7
33 Gilleard O, Goodman A, Cooper M, Davies M, Dunn J: The significance of the Van Nuys prognostic index in the management of ductal carcinoma *in situ*. World J Surg Oncol 6: 61, 2008. DOI: 10.1186/1477-7819-6-61
34 Raldow AC, Sher D, Chen AB, Recht A, Punglia RS: Cost effectiveness of the oncotype DX DCIS score for guiding treatment of patients with ductal carcinoma *in situ*. J Clin Oncol 34(33): 3963-3968, 2016. DOI: 10.1200/JCO.2016.67.8532
35 Shapiro CL, Recht A: Side effects of adjuvant treatment of breast cancer. N Engl J Med 344(26): 1997-2008, 2001. DOI: 10.1056/NEJM200106283442607
36 Hwang ES, Hyslop T, Lynch T, Ryser MD, Weiss A, Wolf A, Norris K, Witten M, Grimm L, Schnitt S, Badve S, Factor R, Frank E, Collyar D, Basila D, Pinto D, Watson MA, West R, Davies L, Donovan JL, Shimada A, Li Y, Li Y, Bennett AV, Rosenberg S, Marks J, Winer E, Boisvert M, Giuliano A, Larson KE, Yost K, McAuliffe PF, Krie A, Tamirisa N, Carey LA, Thompson AM, Partridge AH, COMET Study Investigators: Active monitoring with or without endocrine therapy for low-risk ductal carcinoma *in situ*: The comet randomized clinical trial. JAMA, 2024. DOI: 10.1001/jama.2024.26698
37 Allison KH, Hammond MEH, Dowsett M, McKernin SE, Carey LA, Fitzgibbons PL, Hayes DF, Lakhani SR, Chavez-MacGregor M, Perlmutter J, Perou CM, Regan MM, Rimm DL, Symmans WF, Torlakovic EE, Varella L, Viale G, Weisberg TF, McShane LM, Wolff AC: Estrogen and progesterone receptor testing in breast cancer: American Society of Clinical Oncology/College of American Pathologists Guideline update. Arch Pathol Lab Med 144(5): 545-563, 2020. DOI: 10.5858/arpa.2019-0904-SA
38 Zabrocka E, Newman B, Levey G, Sweeney K, Oentoro J, Ryu S, Stessin A: Estrogen receptor-negative ductal carcinoma *in situ* (DCIS) of the breast – an institutional review of outcomes. Anticancer Res 43(9): 4031-4036, 2023. DOI: 10.21873/anticanres.16591
39 Buerger H, Otterbach F, Simon R, Poremba C, Diallo R, Decker T, Riethdorf L, Brinkschmidt C, Dockhorn-Dworniczak B, Boecker W: Comparative genomic hybridization of ductal carcinoma *in situ* of the breast-evidence of multiple genetic pathways. J Pathol 187(4): 396-402, 1999. DOI: 10.1002/(SICI)1096-9896(199903)187:4<396::AID-PATH286>3.0.CO;2-L
40 Vincent-Salomon A, Lucchesi C, Gruel N, Raynal V, Pierron G, Goudefroye R, Reyal F, Radvanyi F, Salmon R, Thiery JP, Sastre-Garau X, Sigal-Zafrani B, Fourquet A, Delattre O, breast cancer study group of the Institut Curie: Integrated genomic and transcriptomic analysis of ductal carcinoma *in situ* of the breast. Clin Cancer Res 14(7): 1956-1965, 2008. DOI: 10.1158/1078-0432.CCR-07-1465
41 Johnson CE, Gorringe KL, Thompson ER, Opeskin K, Boyle SE, Wang Y, Hill P, Mann GB, Campbell IG: Identification of copy number alterations associated with the progression of DCIS to invasive ductal carcinoma. Breast Cancer Res Treat 133(3): 889-898, 2012. DOI: 10.1007/s10549-011-1835-1
42 Gorringe KL, Hunter SM, Pang JM, Opeskin K, Hill P, Rowley SM, Choong DY, Thompson ER, Dobrovic A, Fox SB, Mann GB, Campbell IG: Copy number analysis of ductal carcinoma *in situ* with and without recurrence. Mod Pathol 28(9): 1174-1184, 2015. DOI: 10.1038/modpathol.2015.75
43 Rane SU, Mirza H, Grigoriadis A, Pinder SE: Selection and evolution in the genomic landscape of copy number alterations in ductal carcinoma *in situ* (DCIS) and its progression to invasive carcinoma of ductal/no special type: a meta-analysis. Breast Cancer Res Treat 153(1): 101-121, 2015. DOI: 10.1007/s10549-015-3509-x
44 Doebar SC, Krol NM, van Marion R, Brouwer RWW, van Ijcken WFJ, Martens JM, Dinjens WNM, van Deurzen CHM: Progression of ductal carcinoma *in situ* to invasive breast cancer: comparative genomic sequencing. Virchows Arch 474(2): 247-251, 2019. DOI: 10.1007/s00428-018-2463-5
45 Trinh A, Gil Del Alcazar CR, Shukla SA, Chin K, Chang YH, Thibault G, Eng J, Jovanović B, Aldaz CM, Park SY, Jeong J, Wu C, Gray J, Polyak K: Genomic alterations during the *in situ* to invasive ductal breast carcinoma transition shaped by the immune system. Mol Cancer Res 19(4): 623-635, 2021. DOI: 10.1158/1541-7786.MCR-20-0949
46 Nagasawa S, Kuze Y, Maeda I, Kojima Y, Motoyoshi A, Onishi T, Iwatani T, Yokoe T, Koike J, Chosokabe M, Kubota M, Seino H, Suzuki A, Seki M, Tsuchihara K, Inoue E, Tsugawa K, Ohta T, Suzuki Y: Genomic profiling reveals heterogeneous populations of ductal carcinoma *in situ* of the breast. Commun Biol 4(1): 438, 2021. DOI: 10.1038/s42003-021-01959-9

47 Pareja F, Brown DN, Lee JY, Da Cruz Paula A, Selenica P, Bi R, Geyer FC, Gazzo A, da Silva EM, Vahdatinia M, Stylianou AA, Ferrando L, Wen HY, Hicks JB, Weigelt B, Reis-Filho JS: Whole-exome sequencing analysis of the progression from non-low-grade ductal carcinoma *in situ* to invasive ductal carcinoma. Clin Cancer Res 26(14): 3682-3693, 2020. DOI: 10.1158/1078-0432.CCR-19-2563

48 Perou CM, Sørlie T, Eisen MB, van de Rijn M, Jeffrey SS, Rees CA, Pollack JR, Ross DT, Johnsen H, Akslen LA, Fluge O, Pergamenschikov A, Williams C, Zhu SX, Lønning PE, Børresen-Dale AL, Brown PO, Botstein D: Molecular portraits of human breast tumours. Nature 406(6797): 747-752, 2000. DOI: 10.1038/35021093

49 Sørlie T, Perou CM, Tibshirani R, Aas T, Geisler S, Johnsen H, Hastie T, Eisen MB, van de Rijn M, Jeffrey SS, Thorsen T, Quist H, Matese JC, Brown PO, Botstein D, Lønning PE, Børresen-Dale AL: Gene expression patterns of breast carcinomas distinguish tumor subclasses with clinical implications. Proc Natl Acad Sci USA 98(19): 10869-10874, 2001. DOI: 10.1073/pnas.191367098

50 Zhou W, Jirström K, Johansson C, Amini RM, Blomqvist C, Agbaje O, Wärnberg F: Long-term survival of women with basal-like ductal carcinoma *in situ* of the breast: a population-based cohort study. BMC Cancer 10: 653, 2010. DOI: 10.1186/1471-2407-10-653

51 Roses RE, Paulson EC, Sharma A, Schueller JE, Nisenbaum H, Weinstein S, Fox KR, Zhang PJ, Czerniecki BJ: HER-2/neu overexpression as a predictor for the transition from *in situ* to invasive breast cancer. Cancer Epidemiol Biomarkers Prev 18(5): 1386-1389, 2009. DOI: 10.1158/1055-9965.EPI-08-1101

52 Yang Y, Zhao X, Wang X, Jin K, Luo J, Yang Z, Mei X, Ma J, Shao Z, Zhang Z, Chen X, Guo X, Yu X: Molecular subtypes predict second breast events of ductal carcinoma *in situ* after breast-conserving surgery. Cancer Med 11(14): 2755-2766, 2022. DOI: 10.1002/cam4.4651

53 Yang L, Shen M, Qiu Y, Tang T, Bu H: Molecular subtyping reveals uniqueness of prognosis in breast ductal carcinoma *in situ* patients with lumpectomy. Breast 64: 1-6, 2022. DOI: 10.1016/j.breast.2022.03.019

54 Kerlikowske K, Molinaro AM, Gauthier ML, Berman HK, Waldman F, Bennington J, Sanchez H, Jimenez C, Stewart K, Chew K, Ljung BM, Tlsty TD: Biomarker expression and risk of subsequent tumors after initial ductal carcinoma *in situ* diagnosis. J Natl Cancer Inst 102(9): 627-637, 2010. DOI: 10.1093/jnci/djq101

55 Stackievicz R, Paran H, Bernheim J, Shapira M, Weisenberg N, Kaufman T, Klein E, Gutman M: Prognostic significance of her-2/neu expression in patients with ductal carcinoma *in situ*. Isr Med Assoc J 12(5): 290-295, 2010.

56 Cobleigh MA, Anderson SJ, Siziopikou KP, Arthur DW, Rabinovitch R, Julian TB, Parda DS, Seaward SA, Carter DL, Lyons JA, Dillmon MS, Magrinat GC, Kavadi VS, Zibelli AM, Tiriveedhi L, Hill ML, Melnik MK, Beriwal S, Mamounas EP, Wolmark N: Comparison of radiation with or without concurrent trastuzumab for HER2-positive ductal carcinoma *in situ* resected by lumpectomy: a phase III clinical trial. J Clin Oncol 39(21): 2367-2374, 2021. DOI: 10.1200/JCO.20.02824

57 Gradishar WJ, Moran MS, Abraham J, Aft R, Agnese D, Allison KH, Anderson B, Burstein HJ, Chew H, Dang C, Elias AD, Giordano SH, Goetz MP, Goldstein LJ, Hurvitz SA, Isakoff SJ, Jankowitz RC, Javid SH, Krishnamurthy J, Leitch M, Lyons J, Mortimer J, Patel SA, Pierce LJ, Rosenberger LH, Rugo HS, Sitapati A, Smith KL, Smith ML, Soliman H, Stringer-Reasor EM, Telli ML, Ward JH, Wisinski KB, Young JS, Burns J, Kumar R: Breast Cancer, Version 3.2022, NCCN Clinical Practice Guidelines in Oncology. J Natl Compr Canc Netw 20(6): 691-722, 2022. DOI: 10.6004/jnccn.2022.0030

58 Hanahan D, Weinberg RA: The Hallmarks of Cancer. Cell 100(1): 57-70, 2000. DOI: 10.1016/s0092-8674(00)81683-9

59 Perez AA, Balabram D, Rocha RM, da Silva Souza Á, Gobbi H: Co-expression of p16, Ki67 and COX-2 is associated with basal phenotype in high-grade ductal carcinoma *in situ* of the breast. J Histochem Cytochem 63(6): 408-416, 2015. DOI: 10.1369/0022155415576540

60 Shim V, Gauthier ML, Sudilovsky D, Mantei K, Chew KL, Moore DH, Cha I, Tlsty TD, Esserman LJ: Cyclooxygenase-2 expression is related to nuclear grade in ductal carcinoma *in situ* and is increased in its normal adjacent epithelium. Cancer Res 63(10): 2347-2350, 2003.

61 Watanabe O, Shimizu T, Imamura H, Kinoshita J, Utada Y, Okabe T, Kimura K, Hirano A, Yoshimatsu K, Aiba M, Ogawa K: Expression of cyclooxygenase-2 in malignant and benign breast tumors. Anticancer Res 23(4): 3215-3221, 2003.

62 Boland GP, Butt IS, Prasad R, Knox WF, Bundred NJ: COX-2 expression is associated with an aggressive phenotype in ductal carcinoma *in situ*. Br J Cancer 90(2): 423-429, 2004. DOI: 10.1038/sj.bjc.6601534

63 Hoque A, Menter DG, Sahin AA, Sneige N, Lippman SM: No increased ki67 expression in ductal carcinoma *in situ* associated with invasive breast cancer. Cancer Epidemiol Biomarkers Prev 10(2): 153-154, 2001.

64 Miligy IM, Toss MS, Gorringe KL, Ellis IO, Green AR, Rakha EA: Aurora Kinase A is an independent predictor of invasive recurrence in breast ductal carcinoma *in situ*. Pathobiology 89(6): 382-392, 2022. DOI: 10.1159/000522244

65 Dettogni RS, Stur E, Laus AC, da Costa Vieira RA, Marques MMC, Santana IVV, Pulido JZ, Ribeiro LF, de Jesus Parmanhani N, Agostini LP, Dos Reis RS, de Vargas Wolfgramm Dos Santos E, Alves LNR, Garcia FM, Santos JA, do Prado Ventorim D, Reis RM, Louro ID: Potential biomarkers of ductal carcinoma *in situ* progression. BMC Cancer 20(1): 119, 2020. DOI: 10.1186/s12885-020-6608-y

66 Elsarraj HS, Hong Y, Limback D, Zhao R, Berger J, Bishop SC, Sabbagh A, Oppenheimer L, Harper HE, Tsimelzon A, Huang S, Hilsenbeck SG, Edwards DP, Fontes J, Fan F, Madan R,

Fangman B, Ellis A, Tawfik O, Persons DL, Fields T, Godwin AK, Hagan CR, Swenson-Fields K, Coarfa C, Thompson J, Behbod F: BCL9/STAT3 regulation of transcriptional enhancer networks promote DCIS progression. NPJ Breast Cancer 6: 12, 2020. DOI: 10.1038/s41523-020-0157-z

67 Guo Q, Li VZ, Nichol JN, Huang F, Yang W, Preston SEJ, Talat Z, Lefrère H, Yu H, Zhang G, Basik M, Gonçalves C, Zhan Y, Plourde D, Su J, Torres J, Marques M, Habyan SA, Bijian K, Amant F, Witcher M, Behbod F, McCaffrey L, Alaoui-Jamali M, Giannakopoulos NV, Brackstone M, Postovit LM, Del Rincón SV, Miller WH Jr: MNK1/NODAL signaling promotes invasive progression of breast ductal carcinoma *in situ*. Cancer Res 79(7): 1646-1657, 2019. DOI: 10.1158/0008-5472.CAN-18-1602

68 Zheng ZY, Elsarraj H, Lei JT, Hong Y, Anurag M, Feng L, Kennedy H, Shen Y, Lo F, Zhao Z, Zhang B, Zhang XH, Tawfik OW, Behbod F, Chang EC: Elevated NRAS expression during DCIS is a potential driver for progression to basal-like properties and local invasiveness. Breast Cancer Res 24(1): 68, 2022. DOI: 10.1186/s13058-022-01565-5

69 Behling KC, Tang A, Freydin B, Chervoneva I, Kadakia S, Schwartz GF, Rui H, Witkiewicz AK: Increased SIAH expression predicts ductal carcinoma *in situ* (DCIS) progression to invasive carcinoma. Breast Cancer Res Treat 129(3): 717-724, 2011. DOI: 10.1007/s10549-010-1254-8

70 Al-Kawaz A, Ali R, Toss MS, Miligy IM, Mohammed OJ, Green AR, Madhusudan S, Rakha EA: The frequency and clinical significance of DNA polymerase beta (POLβ) expression in breast ductal carcinoma *in situ* (DCIS). Breast Cancer Res Treat 190(1): 39-51, 2021. DOI: 10.1007/s10549-021-06357-7

71 Al-Kawaz A, Miligy IM, Toss MS, Mohammed OJ, Green AR, Madhusudan S, Rakha EA: The prognostic significance of Flap Endonuclease 1 (FEN1) in breast ductal carcinoma *in situ*. Breast Cancer Res Treat 188(1): 53-63, 2021. DOI: 10.1007/s10549-021-06271-y

72 Treekitkarnmongkol W, Shah V, Kai K, Katayama H, Wong J, Ladha FA, Nguyen T, Menegaz B, Lu W, Yang F, Mino B, Tang X, Gagea M, Batra H, Raso MG, Wistuba II, Krishnamurthy S, Pinder SE, Sawyer EJ, Thompson AM, Sen S: Epigenetic activation of SOX11 is associated with recurrence and progression of ductal carcinoma *in situ* to invasive breast cancer. Br J Cancer 131(1): 171-183, 2024. DOI: 10.1038/s41416-024-02697-5

73 Oliemuller E, Newman R, Tsang SM, Foo S, Muirhead G, Noor F, Haider S, Aurrekoetxea-Rodríguez I, Vivanco MD, Howard BA: SOX11 promotes epithelial/mesenchymal hybrid state and alters tropism of invasive breast cancer cells. Elife 9: e58374, 2020. DOI: 10.7554/eLife.58374

74 Man YG, Tai L, Barner R, Vang R, Saenger JS, Shekitka KM, Bratthauer GL, Wheeler DT, Liang CY, Vinh TN, Strauss BL: Cell clusters overlying focally disrupted mammary myoepithelial cell layers and adjacent cells within the same duct display different immunohistochemical and genetic features: implications for tumor progression and invasion. Breast Cancer Res 5(6): R231-R241, 2003. DOI: 10.1186/bcr653

75 Hu M, Yao J, Carroll DK, Weremowicz S, Chen H, Carrasco D, Richardson A, Violette S, Nikolskaya T, Nikolsky Y, Bauerlein EL, Hahn WC, Gelman RS, Allred C, Bissell MJ, Schnitt S, Polyak K: Regulation of *in situ* to invasive breast carcinoma transition. Cancer Cell 13(5): 394-406, 2008. DOI: 10.1016/j.ccr.2008.03.007

76 Russell TD, Jindal S, Agunbiade S, Gao D, Troxell M, Borges VF, Schedin P: Myoepithelial cell differentiation markers in ductal carcinoma *in situ* progression. Am J Pathol 185(11): 3076-3089, 2015. DOI: 10.1016/j.ajpath.2015.07.004

77 Ding L, Su Y, Fassl A, Hinohara K, Qiu X, Harper NW, Huh SJ, Bloushtain-Qimron N, Jovanović B, Ekram M, Zi X, Hines WC, Alečković M, Gil Del Alcazar C, Caulfield RJ, Bonal DM, Nguyen QD, Merino VF, Choudhury S, Ethington G, Panos L, Grant M, Herlihy W, Au A, Rosson GD, Argani P, Richardson AL, Dillon D, Allred DC, Babski K, Kim EMH, McDonnell CH 3rd, Wagner J, Rowberry R, Bobolis K, Kleer CG, Hwang ES, Blum JL, Cristea S, Sicinski P, Fan R, Long HW, Sukumar S, Park SY, Garber JE, Bissell M, Yao J, Polyak K: Perturbed myoepithelial cell differentiation in BRCA mutation carriers and in ductal carcinoma *in situ*. Nat Commun 10(1): 4182, 2019. DOI: 10.1038/s41467-019-12125-5

78 Allen MD, Marshall JF, Jones JL: αvβ6 Expression in myoepithelial cells: a novel marker for predicting DCIS progression with therapeutic potential. Cancer Res 74(21): 5942-5947, 2014. DOI: 10.1158/0008-5472.CAN-14-1841

79 Hayward MK, Allen MD, Gomm JJ, Goulding I, Thompson CL, Knight MM, Marshall JF, Jones JL: Mechanostimulation of breast myoepithelial cells induces functional changes associated with DCIS progression to invasion. NPJ Breast Cancer 8(1): 109, 2022. DOI: 10.1038/s41523-022-00464-4

80 Lo PK, Zhang Y, Yao Y, Wolfson B, Yu J, Han SY, Duru N, Zhou Q: Tumor-associated myoepithelial cells promote the invasive progression of ductal carcinoma *in situ* through activation of TGFβ signaling. J Biol Chem 292(27): 11466-11484, 2017. DOI: 10.1074/jbc.M117.775080

81 Allen MD, Thomas GJ, Clark S, Dawoud MM, Vallath S, Payne SJ, Gomm JJ, Dreger SA, Dickinson S, Edwards DR, Pennington CJ, Sestak I, Cuzick J, Marshall JF, Hart IR, Jones JL: Altered microenvironment promotes progression of preinvasive breast cancer: myoepithelial expression of αvβ6 integrin in DCIS identifies high-risk patients and predicts recurrence. Clin Cancer Res 20(2): 344-357, 2014. DOI: 10.1158/1078-0432.CCR-13-1504

82 Witkiewicz AK, Dasgupta A, Sotgia F, Mercier I, Pestell RG, Sabel M, Kleer CG, Brody JR, Lisanti MP: An absence of stromal caveolin-1 expression predicts early tumor recurrence and poor clinical outcome in human breast cancers. Am J Pathol 174(6): 2023-2034, 2009. DOI: 10.2353/ajpath.2009.080873

83 Martinez-Outschoorn UE, Pavlides S, Whitaker-Menezes D, Daumer KM, Milliman JN, Chiavarina B, Migneco G,

Witkiewicz AK, Martinez-Cantarin MP, Flomenberg N, Howell A, Pestell RG, Lisanti MP, Sotgia F: Tumor cells induce the cancer associated fibroblast phenotype via caveolin-1 degradation: Implications for breast cancer and DCIS therapy with autophagy inhibitors. Cell Cycle 9(12): 2423-2433, 2010. DOI: 10.4161/cc.9.12.12048

84 Martins D, Beça FF, Sousa B, Baltazar F, Paredes J, Schmitt F: Loss of caveolin-1 and gain of MCT4 expression in the tumor stroma: key events in the progression from an *in situ* to an invasive breast carcinoma. Cell Cycle 12(16): 2684-2690, 2013. DOI: 10.4161/cc.25794

85 Rebbeck CA, Xian J, Bornelöv S, Geradts J, Hobeika A, Geiger H, Alvarez JF, Rozhkova E, Nicholls A, Robine N, Lyerly HK, Hannon GJ: Gene expression signatures of individual ductal carcinoma *in situ* lesions identify processes and biomarkers associated with progression towards invasive ductal carcinoma. Nat Commun 13(1): 3399, 2022. DOI: 10.1038/s41467-022-30573-4

86 Hughes LL, Wang M, Page DL, Gray R, Solin LJ, Davidson NE, Lowen MA, Ingle JN, Recht A, Wood WC: Local excision alone without irradiation for ductal carcinoma *in situ* of the breast: a trial of the Eastern Cooperative Oncology Group. J Clin Oncol 27(32): 5319-5324, 2009. DOI: 10.1200/JCO.2009.21.8560

87 Solin LJ, Gray R, Baehner FL, Butler SM, Hughes LL, Yoshizawa C, Cherbavaz DB, Shak S, Page DL, Sledge GW Jr, Davidson NE, Ingle JN, Perez EA, Wood WC, Sparano JA, Badve S: A multigene expression assay to predict local recurrence risk for ductal carcinoma *in situ* of the breast. J Natl Cancer Inst 105(10): 701-710, 2013. DOI: 10.1093/jnci/djt067

88 Rakovitch E, Sutradhar R, Nofech-Mozes S, Gu S, Fong C, Hanna W, Paszat L: 21-gene assay and breast cancer mortality in ductal carcinoma *in situ*. J Natl Cancer Inst 113(5): 572-579, 2021. DOI: 10.1093/jnci/djaa179

89 Bremer T, Whitworth PW, Patel R, Savala J, Barry T, Lyle S, Leesman G, Linke SP, Jirstrom K, Zhou W, Amini RM, Warnberg F: A biological signature for breast ductal carcinoma *in situ* to predict radiotherapy benefit and assess recurrence risk. Clin Cancer Res 24(23): 5895-5901, 2018. DOI: 10.1158/1078-0432.CCR-18-0842

90 Paik S, Shak S, Tang G, Kim C, Baker J, Cronin M, Baehner FL, Walker MG, Watson D, Park T, Hiller W, Fisher ER, Wickerham DL, Bryant J, Wolmark N: A multigene assay to predict recurrence of tamoxifen-treated, node-negative breast cancer. N Engl J Med 351(27): 2817-2826, 2004. DOI: 10.1056/NEJMoa041588

91 Lasek W: Cancer immunoediting hypothesis: history, clinical implications and controversies. Cent Eur J Immunol 47(2): 168-174, 2022. DOI: 10.5114/ceji.2022.117376

92 Lal A, Chan L, Devries S, Chin K, Scott GK, Benz CC, Chen YY, Waldman FM, Hwang ES: FOXP3-positive regulatory T lymphocytes and epithelial FOXP3 expression in synchronous normal, ductal carcinoma *in situ*, and invasive cancer of the breast. Breast Cancer Res Treat 139(2): 381-390, 2013. DOI: 10.1007/s10549-013-2556-4

93 Kim M, Chung YR, Kim HJ, Woo JW, Ahn S, Park SY: Immune microenvironment in ductal carcinoma *in situ*: a comparison with invasive carcinoma of the breast. Breast Cancer Res 22(1): 32, 2020. DOI: 10.1186/s13058-020-01267-w

94 Mao Y, Qu Q, Chen X, Huang O, Wu J, Shen K: The prognostic value of tumor-infiltrating lymphocytes in breast cancer: a systematic review and meta-analysis. PLoS One 11(4): e0152500, 2016. DOI: 10.1371/journal.pone.0152500

95 Miligy I, Mohan P, Gaber A, Aleskandarany MA, Nolan CC, Diez-Rodriguez M, Mukherjee A, Chapman C, Ellis IO, Green AR, Rakha EA: Prognostic significance of tumour infiltrating B lymphocytes in breast ductal carcinoma *in situ*. Histopathology 71(2): 258-268, 2017. DOI: 10.1111/his.13217

96 Toss MS, Miligy I, Al-Kawaz A, Alsleem M, Khout H, Rida PC, Aneja R, Green AR, Ellis IO, Rakha EA: Prognostic significance of tumor-infiltrating lymphocytes in ductal carcinoma *in situ* of the breast. Mod Pathol 31(8): 1226-1236, 2018. DOI: 10.1038/s41379-018-0040-8

97 Thike AA, Chen X, Koh VCY, Binte Md Nasir ND, Yeong JPS, Bay BH, Tan PH: Higher densities of tumour-infiltrating lymphocytes and $CD4^+$ T cells predict recurrence and progression of ductal carcinoma *in situ* of the breast. Histopathology 76(6): 852-864, 2020. DOI: 10.1111/his.14055

98 Xu FF, Zheng SF, Xu C, Cai G, Wang SB, Qi WX, Wang CF, Chen JY, Lu C: Prognostic and predictive significance of tumor infiltrating lymphocytes for ductal carcinoma *in situ*. Oncoimmunology 10(1): 1875637, 2021. DOI: 10.1080/2162402X.2021.1875637

99 Schiza A, Thurfjell V, Stenmark Tullberg A, Olofsson H, Lindberg A, Holmberg E, Bremer T, Micke P, Karlsson P, Wärnberg F, Strell C: Tumour-infiltrating lymphocytes add prognostic information for patients with low-risk DCIS: findings from the SweDCIS randomised radiotherapy trial. Eur J Cancer 168: 128-137, 2022. DOI: 10.1016/j.ejca.2022.01.016

100 Li H, Aggarwal A, Toro P, Fu P, Badve SS, Cuzick J, Madabhushi A, Thorat MA: A prognostic and predictive computational pathology immune signature for ductal carcinoma *in situ*: retrospective results from a cohort within the UK/ANZ DCIS trial. Lancet Digit Health 6(8): e562-e569, 2024. DOI: 10.1016/S2589-7500(24)00116-X

101 Thompson E, Taube JM, Elwood H, Sharma R, Meeker A, Warzecha HN, Argani P, Cimino-Mathews A, Emens LA: The immune microenvironment of breast ductal carcinoma *in situ*. Mod Pathol 29(3): 249-258, 2016. DOI: 10.1038/modpathol.2015.158

102 Hendry S, Pang JB, Byrne DJ, Lakhani SR, Cummings MC, Campbell IG, Mann GB, Gorringe KL, Fox SB: Relationship of the breast ductal carcinoma *in situ* immune microenvironment with clinicopathological and genetic features. Clin Cancer Res 23(17): 5210-5217, 2017. DOI: 10.1158/1078-0432.CCR-17-0743

103 Pruneri G, Lazzeroni M, Bagnardi V, Tiburzio GB, Rotmensz N, DeCensi A, Guerrieri-Gonzaga A, Vingiani A, Curigliano G, Zurrida S, Bassi F, Salgado R, Van den Eynden G, Loi S, Denkert C, Bonanni B, Viale G: The prevalence and clinical relevance of tumor-infiltrating lymphocytes (TILs) in ductal carcinoma *in situ* of the breast. Ann Oncol 28(2): 321-328, 2017. DOI: 10.1093/annonc/mdw623
104 Gil Del Alcazar CR, Huh SJ, Ekram MB, Trinh A, Liu LL, Beca F, Zi X, Kwak M, Bergholtz H, Su Y, Ding L, Russnes HG, Richardson AL, Babski K, Min Hui Kim E, McDonnell CH 3rd, Wagner J, Rowberry R, Freeman GJ, Dillon D, Sorlie T, Coussens LM, Garber JE, Fan R, Bobolis K, Allred DC, Jeong J, Park SY, Michor F, Polyak K: Immune escape in breast cancer during *in situ* to invasive carcinoma transition. Cancer Discov 7(10): 1098-1115, 2017. DOI: 10.1158/2159-8290.CD-17-0222
105 Arlauckas SP, Garris CS, Kohler RH, Kitaoka M, Cuccarese MF, Yang KS, Miller MA, Carlson JC, Freeman GJ, Anthony RM, Weissleder R, Pittet MJ: *In vivo* imaging reveals a tumor-associated macrophage-mediated resistance pathway in anti-PD-1 therapy. Sci Transl Med 9(389): eaal3604, 2017. DOI: 10.1126/scitranslmed.aal3604
106 Gwak JM, Jang MH, Kim DI, Seo AN, Park SY: Prognostic value of tumor-associated macrophages according to histologic locations and hormone receptor status in breast cancer. PLoS One 10(4): e0125728, 2015. DOI: 10.1371/journal.pone.0125728
107 Santoni M, Romagnoli E, Saladino T, Foghini L, Guarino S, Capponi M, Giannini M, Cognigni PD, Ferrara G, Battelli N: Triple negative breast cancer: Key role of Tumor-Associated Macrophages in regulating the activity of anti-PD-1/PD-L1 agents. Biochim Biophys Acta Rev Cancer 1869(1): 78-84, 2018. DOI: 10.1016/j.bbcan.2017.10.007
108 Yuan ZY, Luo RZ, Peng RJ, Wang SS, Xue C: High infiltration of tumor-associated macrophages in triple-negative breast cancer is associated with a higher risk of distant metastasis. Onco Targets Ther 7: 1475-1480, 2014. DOI: 10.2147/OTT.S61838
109 Wang S, Wang J, Chen Z, Luo J, Guo W, Sun L, Lin L: Targeting M2-like tumor-associated macrophages is a potential therapeutic approach to overcome antitumor drug resistance. NPJ Precis Oncol 8(1): 31, 2024. DOI: 10.1038/s41698-024-00522-z
110 Carron EC, Homra S, Rosenberg J, Coffelt SB, Kittrell F, Zhang Y, Creighton CJ, Fuqua SA, Medina D, Machado HL: Macrophages promote the progression of premalignant mammary lesions to invasive cancer. Oncotarget 8(31): 50731-50746, 2017. DOI: 10.18632/oncotarget.14913
111 McKee GT, Tildsley G, Hammond S: Cytologic diagnosis and grading of ductal carcinoma *in situ*. Cancer 87(4): 203-209, 1999.
112 Chen XY, Thike AA, Md Nasir ND, Koh VCY, Bay BH, Tan PH: Higher density of stromal M2 macrophages in breast ductal carcinoma *in situ* predicts recurrence. Virchows Arch 476(6): 825-833, 2020. DOI: 10.1007/s00428-019-02735-1
113 Hoskoppal D, Reisenbichler ES: Can tumor-associated macrophages in ductal carcinoma *in situ* on biopsy predict invasive carcinoma on excision? Hum Pathol 82: 158-162, 2018. DOI: 10.1016/j.humpath.2018.07.023
114 Hong R, Cao B, Chen D, Wu W, Luo T, Lv D, Zhang W, Wang S, Shao K: Multi-omics portrait of ductal carcinoma *in situ* in young women. Breast Cancer Res Treat 206(1): 105-118, 2024. DOI: 10.1007/s10549-024-07254-5
115 Acevedo DS, Fang WB, Rao V, Penmetcha V, Leyva H, Acosta G, Cote P, Brodine R, Swerdlow R, Tan L, Lorenzi PL, Cheng N: Regulation of growth, invasion and metabolism of breast ductal carcinoma through CCL2/CCR2 signaling interactions with MET receptor tyrosine kinases. Neoplasia 28: 100791, 2022. DOI: 10.1016/j.neo.2022.100791
116 Shaker H, Bundred NJ, Landberg G, Pritchard SA, Albadry H, Nicholson SL, Harries LJ, Heah JYE, Castle J, Kirwan CC: Breast cancer stromal clotting activation (Tissue Factor and thrombin): A pre-invasive phenomena that is prognostic in invasion. Cancer Med 9(5): 1768-1778, 2020. DOI: 10.1002/cam4.2748
117 Yu LN, Liu Z, Tian Y, Zhao PP, Hua X: FAP-a and GOLPH3 are hallmarks of DCIS progression to invasive breast cancer. Front Oncol 9: 1424, 2019. DOI: 10.3389/fonc.2019.01424
118 Hua X, Huang X, Liao Z, Xian Q, Yu L: [Changes of fibroblast immunophenotype and their clinical significance in stromal remodeling of breast tumors]. Zhonghua Zhong Liu Za Zhi 36(11): 834-838, 2014.
119 Lesurf R, Aure MR, Mørk HH, Vitelli V, Oslo Breast Cancer Research Consortium (OSBREAC), Lundgren S, Børresen-Dale AL, Kristensen V, Wärnberg F, Hallett M, Sørlie T: Molecular features of subtype-specific progression from ductal carcinoma *in situ* to invasive breast cancer. Cell Rep 16(4): 1166-1179, 2016. DOI: 10.1016/j.celrep.2016.06.051
120 Strell C, Paulsson J, Jin SB, Tobin NP, Mezheyeuski A, Roswall P, Mutgan C, Mitsios N, Johansson H, Wickberg SM, Svedlund J, Nilsson M, Hall P, Mulder J, Radisky DC, Pietras K, Bergh J, Lendahl U, Wärnberg F, Östman A: Impact of epithelial-stromal interactions on peritumoral fibroblasts in ductal carcinoma *in situ*. J Natl Cancer Inst 111(9): 983-995, 2019. DOI: 10.1093/jnci/djy234
121 Croizer H, Mhaidly R, Kieffer Y, Gentric G, Djerroudi L, Leclere R, Pelon F, Robley C, Bohec M, Meng A, Meseure D, Romano E, Baulande S, Peltier A, Vincent-Salomon A, Mechta-Grigoriou F: Deciphering the spatial landscape and plasticity of immunosuppressive fibroblasts in breast cancer. Nat Commun 15(1): 2806, 2024. DOI: 10.1038/s41467-024-47068-z
122 Brummer G, Acevedo DS, Hu Q, Portsche M, Fang WB, Yao M, Zinda B, Myers M, Alvarez N, Fields P, Hong Y, Behbod F, Cheng N: Chemokine signaling facilitates early-stage breast cancer survival and invasion through fibroblast-dependent

mechanisms. Mol Cancer Res 16(2): 296-308, 2018. DOI: 10.1158/1541-7786.MCR-17-0308

123 Osuala KO, Sameni M, Shah S, Aggarwal N, Simonait ML, Franco OE, Hong Y, Hayward SW, Behbod F, Mattingly RR, Sloane BF: Il-6 signaling between ductal carcinoma *in situ* cells and carcinoma-associated fibroblasts mediates tumor cell growth and migration. BMC Cancer 15: 584, 2015. DOI: 10.1186/s12885-015-1576-3

124 Campbell MJ, Baehner F, O'Meara T, Ojukwu E, Han B, Mukhtar R, Tandon V, Endicott M, Zhu Z, Wong J, Krings G, Au A, Gray JW, Esserman L: Characterizing the immune microenvironment in high-risk ductal carcinoma *in situ* of the breast. Breast Cancer Res Treat 161(1): 17-28, 2017. DOI: 10.1007/s10549-016-4036-0

125 Almekinders MM, Bismeijer T, Kumar T, Yang F, Thijssen B, van der Linden R, van Rooijen C, Vonk S, Sun B, Parra Cuentas ER, Wistuba II, Krishnamurthy S, Visser LL, Seignette IM, Hofland I, Sanders J, Broeks A, Love JK, Menegaz B, Wessels L, Thompson AM, de Visser KE, Hooijberg E, Lips E, Futreal A, Wesseling J, Grand Challenge PRECISION Consortium: Comprehensive multiplexed immune profiling of the ductal carcinoma *in situ* immune microenvironment regarding subsequent ipsilateral invasive breast cancer risk. Br J Cancer 127(7): 1201-1213, 2022. DOI: 10.1038/s41416-022-01888-2

126 Risom T, Glass DR, Averbukh I, Liu CC, Baranski A, Kagel A, McCaffrey EF, Greenwald NF, Rivero-Gutiérrez B, Strand SH, Varma S, Kong A, Keren L, Srivastava S, Zhu C, Khair Z, Veis DJ, Deschryver K, Vennam S, Maley C, Hwang ES, Marks JR, Bendall SC, Colditz GA, West RB, Angelo M: Transition to invasive breast cancer is associated with progressive changes in the structure and composition of tumor stroma. Cell 185(2): 299-310.e18, 2022. DOI: 10.1016/j.cell.2021.12.023

127 Mitchell E, Jindal S, Chan T, Narasimhan J, Sivagnanam S, Gray E, Chang YH, Weinmann S, Schedin P: Loss of myoepithelial calponin-1 characterizes high-risk ductal carcinoma *in situ* cases, which are further stratified by T cell composition. Mol Carcinog 59(7): 701-712, 2020. DOI: 10.1002/mc.23171

128 Buell P, Dunn JE: Cancer mortality among Japanese ISSEI and NISEI of California. Cancer 18(5): 656-664, 1965. DOI: 10.1002/1097-0142(196505)18:5<656::aid-cncr2820180515>3.0.co;2-3

129 Soares J, Pinto AE, Cunha CV, André S, Barão I, Sousa JM, Cravo M: Global DNA hypomethylation in breast carcinoma: Correlation with prognostic factors and tumor progression. Cancer 85(1): 112-118, 1999.

130 Cheung HH, Lee TL, Rennert OM, Chan WY: DNA methylation of cancer genome. Birth Defects Res C Embryo Today 87(4): 335-350, 2009. DOI: 10.1002/bdrc.20163

131 DeVaux RS, Herschkowitz JI: Beyond DNA: the role of epigenetics in the premalignant progression of breast cancer. J Mammary Gland Biol Neoplasia 23(4): 223-235, 2018. DOI: 10.1007/s10911-018-9414-2

132 Faryna M, Konermann C, Aulmann S, Bermejo JL, Brugger M, Diederichs S, Rom J, Weichenhan D, Claus R, Rehli M, Schirmacher P, Sinn HP, Plass C, Gerhauser C: Genome-wide methylation screen in low-grade breast cancer identifies novel epigenetically altered genes as potential biomarkers for tumor diagnosis. FASEB J 26(12): 4937-4950, 2012. DOI: 10.1096/fj.12-209502

133 Parrella P, Poeta ML, Gallo AP, Prencipe M, Scintu M, Apicella A, Rossiello R, Liguoro G, Seripa D, Gravina C, Rabitti C, Rinaldi M, Nicol T, Tommasi S, Paradiso A, Schittulli F, Altomare V, Fazio VM: Nonrandom distribution of aberrant promoter methylation of cancer-related genes in sporadic breast tumors. Clin Cancer Res 10(16): 5349-5354, 2004. DOI: 10.1158/1078-0432.CCR-04-0555

134 van Hoesel AQ, Sato Y, Elashoff DA, Turner RR, Giuliano AE, Shamonki JM, Kuppen PJ, van de Velde CJ, Hoon DS: Assessment of DNA methylation status in early stages of breast cancer development. Br J Cancer 108(10): 2033-2038, 2013. DOI: 10.1038/bjc.2013.136

135 Fleischer T, Frigessi A, Johnson KC, Edvardsen H, Touleimat N, Klajic J, Riis ML, Haakensen VD, Wärnberg F, Naume B, Helland A, Børresen-Dale AL, Tost J, Christensen BC, Kristensen VN: Genome-wide DNA methylation profiles in progression to *in situ* and invasive carcinoma of the breast with impact on gene transcription and prognosis. Genome Biol 15(8): 435, 2014. DOI: 10.1186/PREACCEPT-2333349012841587

136 Moelans CB, Verschuur-Maes AH, van Diest PJ: Frequent promoter hypermethylation of BRCA2, CDH13, MSH6, PAX5, PAX6 and WT1 in ductal carcinoma *in situ* and invasive breast cancer. J Pathol 225(2): 222-231, 2011. DOI: 10.1002/path.2930

137 Lehmann U, Länger F, Feist H, Glöckner S, Hasemeier B, Kreipe H: Quantitative assessment of promoter hypermethylation during breast cancer development. Am J Pathol 160(2): 605-612, 2002. DOI: 10.1016/S0002-9440(10)64880-8

138 Muggerud AA, Rønneberg JA, Wärnberg F, Botling J, Busato F, Jovanovic J, Solvang H, Bukholm I, Børresen-Dale AL, Kristensen VN, Sørlie T, Tost J: Frequent aberrant DNA methylation of ABCB1, FOXC1, PPP2R2B and PTEN in ductal carcinoma *in situ* and early invasive breast cancer. Breast Cancer Res 12(1): R3, 2010. DOI: 10.1186/bcr2466

139 Pang JM, Dobrovic A, Fox SB: DNA methylation in ductal carcinoma *in situ* of the breast. Breast Cancer Res 15(3): 206, 2013. DOI: 10.1186/bcr3420

140 Park SY, Kwon HJ, Lee HE, Ryu HS, Kim S, Kim JH, Kim IA, Jung N, Cho NY, Kang GH: Promoter CpG island hypermethylation during breast cancer progression. Virchows Arch 458(1): 73-84, 2011. DOI: 10.1007/s00428-010-1013-6

141 Bergholtz H, Lien TG, Swanson DM, Frigessi A, Oslo Breast Cancer Research Consortium (OSBREAC), Daidone MG, Tost J, Wärnberg F, Sørlie T: Contrasting DCIS and invasive breast cancer by subtype suggests basal-like DCIS as distinct lesions.

NPJ Breast Cancer 6: 26, 2020. DOI: 10.1038/s41523-020-0167-x
142 Johnson KC, Koestler DC, Fleischer T, Chen P, Jenson EG, Marotti JD, Onega T, Kristensen VN, Christensen BC: DNA methylation in ductal carcinoma *in situ* related with future development of invasive breast cancer. Clin Epigenetics 7(1): 75, 2015. DOI: 10.1186/s13148-015-0094-0
143 Abba MC, Canzoneri R, Gurruchaga A, Lee J, Tatineni P, Kil H, Lacunza E, Aldaz CM: LINC00885 a novel oncogenic long non-coding RNA associated with early stage breast cancer progression. Int J Mol Sci 21(19): 7407, 2020. DOI: 10.3390/ijms21197407
144 Abba MC, Fabre ML, Lee J, Tatineni P, Kil H, Aldaz CM: HOTAIR modulated pathways in early-stage breast cancer progression. Front Oncol 11: 783211, 2021. DOI: 10.3389/fonc.2021.783211
145 Deshpande RP, Sharma S, Liu Y, Pandey PR, Pei X, Wu K, Wu SY, Tyagi A, Zhao D, Mo YY, Watabe K: LncRNA IPW inhibits growth of ductal carcinoma *in situ* by downregulating ID2 through miR-29c. Breast Cancer Res 24(1): 6, 2022. DOI: 10.1186/s13058-022-01504-4